

2003

# Pathologic and hematologic alterations caused by *Leptospira kirschneri* serovar Grippytyphosa and *Leptospira interrogans* serovar Pomona

Justin Jay Greenlee  
*Iowa State University*

Follow this and additional works at: <https://lib.dr.iastate.edu/rtd>

 Part of the [Veterinary Pathology and Pathobiology Commons](#)

## Recommended Citation

Greenlee, Justin Jay, "Pathologic and hematologic alterations caused by *Leptospira kirschneri* serovar Grippytyphosa and *Leptospira interrogans* serovar Pomona " (2003). *Retrospective Theses and Dissertations*. 715.  
<https://lib.dr.iastate.edu/rtd/715>

This Dissertation is brought to you for free and open access by the Iowa State University Capstones, Theses and Dissertations at Iowa State University Digital Repository. It has been accepted for inclusion in Retrospective Theses and Dissertations by an authorized administrator of Iowa State University Digital Repository. For more information, please contact [digirep@iastate.edu](mailto:digirep@iastate.edu).

# NOTE TO USERS

This reproduction is the best copy available.

**UMI**<sup>®</sup>



**Pathologic and hematologic alterations caused by *Leptospira kirschneri*  
serovar Grippotyphosa and *Leptospira interrogans* serovar Pomona**

by

**Justin Jay Greenlee**

A dissertation submitted to the graduate faculty  
in partial fulfillment of the requirements for the degree of  
**DOCTOR OF PHILOSOPHY**

Major: Veterinary Pathology

Program of Study Committee:

Claire B. Andreasen (Co-Major Professor)

Carole A. Bolin (Co-Major Professor)

Mark R. Ackermann

Norman F. Cheville

Douglas E. Jones

Steven D. Sorden

Richard L. Zuerner

Iowa State University

Ames, Iowa

2003

UMI Number: 3118229

### INFORMATION TO USERS

The quality of this reproduction is dependent upon the quality of the copy submitted. Broken or indistinct print, colored or poor quality illustrations and photographs, print bleed-through, substandard margins, and improper alignment can adversely affect reproduction.

In the unlikely event that the author did not send a complete manuscript and there are missing pages, these will be noted. Also, if unauthorized copyright material had to be removed, a note will indicate the deletion.

**UMI**<sup>®</sup>

---

UMI Microform 3118229

Copyright 2004 by ProQuest Information and Learning Company.

All rights reserved. This microform edition is protected against unauthorized copying under Title 17, United States Code.

ProQuest Information and Learning Company  
300 North Zeeb Road  
P.O. Box 1346  
Ann Arbor, MI 48106-1346

Graduate College  
Iowa State University

This is to certify that the doctoral dissertation of  
Justin Jay Greenlee  
has met the dissertation requirements of Iowa State University

Signature was redacted for privacy.

Co-major Professor

Signature was redacted for privacy.

Co-major Professor

Signature was redacted for privacy.

For the Major Program

## TABLE OF CONTENTS

### CHAPTER 1. GENERAL INTRODUCTION

Introduction	1
Dissertation Organization	3
Literature Review	4
References	23

### CHAPTER 2. CLINICAL AND PATHOLOGIC COMPARISON OF ACUTE CANINE LEPTOSPIROSIS CAUSED BY TWO STRAINS OF *LEPTOSPIRA* *KIRSCHNERI* SEROVAR GRIPPOTYPHOSA

Abstract	33
Introduction	34
Materials and Methods	35
Results	41
Discussion	48
References	52
Acknowledgements	54

### CHAPTER 3. EXPERIMENTAL CANINE LEPTOSPIROSIS CAUSED BY *LEPTOSPIRA INTERROGANS* SEROVARS POMONA AND BRATISLAVA

Abstract	55
Introduction	56
Materials and Methods	57
Results	62

Discussion	72
References	74
Acknowledgements	76
CHAPTER 4. <i>LEPTOSPIRA INTERROGANS</i> SEROVAR POMONA INFECTION IN GUINEA PIGS AND <i>IN VITRO</i> EVIDENCE OF LEPTOSPIRE BINDING OF PLATELETS	77
Abstract	77
Introduction	78
Materials and Methods	79
Results	86
Discussion	92
References	94
Acknowledgements	96
CHAPTER 5. GENERAL CONCLUSIONS	97
References	101
APPENDIX. PRELIMINARY PLATELET FUNCTION STUDIES IN SEROVAR POMONA INFECTED DOGS	102



## CHAPTER 1. GENERAL INTRODUCTION

Leptospirosis, a disease caused by bacteria of the genus *Leptospira*, occurs in a wide range of mammalian hosts worldwide, including human beings. Exposure usually occurs after leptospire are excreted in the urine of an infected maintenance host that asymptotically harbors bacteria in its kidneys. Infection can result from direct contact with infectious blood or urine or indirect contact with soil or water contaminated with infectious urine. Slaughterhouse workers, swine producers, and dairy workers are at risk of occupational exposure, and recently, infections have been documented as a result of changing modes of human interaction with the environment including outdoor leisure activities, water sports, and adventure tourism. In some urban areas, the risk of infection to humans and companion animals has increased due to increased numbers of reservoirs.

After entering the body through mucous membrane contact or abraded skin, bacteria replicate in the bloodstream or organs. The onset of clinical signs occurs in 3 to 20 days. Signs are initially non-specific and include lethargy, anorexia, fever, and myalgia. Signs may progress to include vomiting, diarrhea, bleeding tendencies, icterus, and death. Exposure to leptospire results in a humoral immune response to the dominant leptospiral antigen, lipopolysaccharide (LPS). An adequate antibody response clears bacteria from the bloodstream and abates clinical signs. However, antibodies do not reach leptospire harbored in the renal tubules, so leptospire may be shed in the urine. In this manner, the cycle of disease continues allowing another animal to be infected.

Canine leptospirosis has been known since 1899. Historically, the most common causes of canine leptospirosis have been *Leptospira interrogans* serovars Icterohaemorrhagiae and Canicola. Vaccines have been available for these serovars and the

incidence of disease has decreased. Since 1983, the incidence of leptospirosis in dogs has significantly increased and has been associated with different serovars. Serological data and bacterial isolation suggests that *Leptospira kirschneri* serovar Grippotyphosa and *Leptospira interrogans* serovars Pomona and Bratislava are now the most common causes of leptospirosis in dogs. Until recently, vaccines were not available for protection against these serovars, and serovar Bratislava still is not included in commercially available canine vaccines in the United States.

Study of these emerging serovars is necessary to allow for the development of new prevention strategies and treatment regimens. Case reports and retrospective studies have provided some information on serovars Grippotyphosa, Pomona, and Bratislava, but complete experimental studies have not been done. Experimental studies provide information on clinical signs, biochemical and hematologic abnormalities, and course of disease that benefits practicing veterinarians. In addition, the development of a regimen that can be used to test various leptospiral isolates is critical to rigorous testing of prevention and treatment protocols in an organized, repeatable way. The objectives of the experiments described in this dissertation were to: 1) use a model of canine leptospirosis to describe the clinical and pathologic abnormalities caused by infection with *Leptospira interrogans* serovars Pomona and Bratislava and *Leptospira kirschneri* serovar Grippotyphosa, 2) characterize hemorrhagic lesions in a guinea pig model of *Leptospira interrogans* serovar Pomona infection, and 3) test the hypothesis that leptospires bind platelets *in vitro*.

### **Dissertation Organization**

This dissertation is organized to include one chapter containing a manuscript submitted for publication and two additional chapters containing manuscripts prepared for publication. These chapters follow the General Introduction and Literature Review. The first manuscript, “Clinical and pathologic comparison of acute canine leptospirosis caused by two strains of *Leptospira kirschneri* serovar Grippotyphosa” relates the clinicopathologic abnormalities and the lesions caused by these bacteria. The second manuscript, “Experimental canine leptospirosis caused by *Leptospira interrogans* serovars Pomona and Bratislava” describes the features of disease in dogs caused by these two emerging serovars. The third manuscript, “*Leptospira interrogans* serovar Pomona infection in guinea pigs and *in vitro* evidence of leptospire binding of platelets” demonstrates that *Leptospira interrogans* serovar Pomona causes hemorrhages in guinea pigs and provides support for the hypothesis that leptospire interact directly with platelets. The final chapter contains a General Discussion of this work.

## Literature Review

### Leptospirosis and *Leptospira*

Leptospirosis, one of the most widespread zoonotic diseases,<sup>1</sup> is a reemerging disease of dogs<sup>2</sup> and humans,<sup>3,4</sup> especially those living in urban centers.<sup>5</sup> The clinical syndrome of leptospiral infection was first described in 1886,<sup>6</sup> and the causative agent of leptospirosis (Weil's disease) described in 1915.<sup>7</sup> Severe infections can cause pulmonary, renal, and hepatic failure. Leptospirosis can affect virtually all warm-blooded animals<sup>8</sup> and leptospires have been isolated from reptiles, amphibians, fish, birds, and invertebrates throughout the world.<sup>5</sup>

### Environment and culture

Leptospires survive in warm, moist environments in neutral to slightly alkaline pH, and are able to retain their pathogenicity outside the host for as long as six months,<sup>9, 10</sup> but replication occurs only inside the host in natural conditions.<sup>11</sup> Saprophytic leptospires are able to grow at much lower temperatures.<sup>12</sup> Chlorine, sea water, acidic pH and drying destroy leptospires.<sup>13</sup> Leptospires can be grown in aerobic culture, and the most common media contain Tween as a carbon source and ammonium salts as a source of nitrogen.<sup>12, 14</sup> Leptospires do not synthesize fatty acids, but rather degrade them by  $\beta$ -oxidation.<sup>15</sup> Leptospire resistance to 5-fluorouracil is exploited to reduce the growth of contaminants in culture.<sup>16</sup>

### Nomenclature

Spirochetes were first described in 1833, and today the order Spirochaetales contains the families Leptospiraceae and Spirochaetaceae, which contain *Leptospira*, *Leptonema*, *Turneria*; and *Brachyspira*, *Treponema*, and *Borrelia*, respectively.<sup>9</sup> New isolates of

*Leptospira* continue to be discovered and the nomenclature has changed to keep up with more modern genetic means of differentiating these isolates. Previously, pathogenic leptospire were recognized as one species, *Leptospira interrogans*, with saprophytic strains classified as *Leptospira biflexa*. Although serovar distinctions are still used, genetic analysis has resulted in division of the genus *Leptospira* into at least 17 species under which over 268 serovars are categorized.<sup>17</sup> Serovar distinctions are the result of serologic categorization of isolates based on an agglutination reaction to homologous antiserum, due to slightly different epitopes in the outer membrane lipopolysaccharide.<sup>18</sup>

### **Morphology**

Leptospire are aerobic spirochetes measuring 0.1  $\mu\text{m}$  wide and 6-20  $\mu\text{m}$  long with hooked ends. Contained within a fluid outer membrane are a helical cell cylinder and two periplasmic flagella. The outer membrane is approximately 11 nm wide<sup>19</sup> and is composed of 3 to 5 electron-dense layers.<sup>20, 21</sup> The inner protoplasmic cylinder contains two circular chromosomes of approximately 4500 kb and 350 kb, respectively.<sup>22, 23</sup> The flagella reside within the periplasmic space, are attached near the terminus of the protoplasmic cylinder, and extend toward the center of the bacterium which help maintain cell shape and allow for motility.<sup>24</sup>

Structurally, leptospire share characteristics with gram-negative bacteria. Spirochetes and gram-negative bacteria have a lipopolysaccharide (LPS) dominated outer membrane that serves as a permeability barrier, protecting them from harsh environmental conditions.

## **Virulence attributes**

### **Attachment**

To be effective pathogens most bacteria use specific mechanisms to adhere to host cells.<sup>25</sup> Attachment properties may be related to virulence as virulent leptospire have greater attachment to the extracellular matrix proteins fibronectin,<sup>26</sup> collagen, and laminin than avirulent lines.<sup>27,28</sup> Leptospire attach to cultured epithelial cells,<sup>29</sup> fibroblasts,<sup>30</sup> endothelial cells,<sup>31</sup> and macrophages.<sup>32</sup> Immunogold labeling suggests an initial interaction with cell surface membranes of hepatocytes, renal tubular epithelium, and renal interstitial endothelium before internalization and cell damage occur.<sup>33</sup> Leptospire adhere to phagocytes in the absence of specific antibodies by binding the CR3 integrin (CD11b/CD18).<sup>34</sup> Leptospiral immunoglobulin-like (Lig) proteins localized on the bacterial surface comprise one mechanism of host cell attachment.<sup>35</sup>

### **Motility**

Motility is conferred by rotation of the periplasmic flagellum within the periplasmic space generating a spiral-shaped wave in the outer membrane sheath while the protoplasmic cylinder rolls around the flagella in the opposite direction.<sup>24</sup> This corkscrew motility allows movement in viscous environments<sup>36</sup> at a greater velocity than low-viscosity media,<sup>24</sup> and may aid in colonization of environments where the immune system is less efficient (i.e. eye).<sup>9</sup> Leptospire can penetrate tight junctions in endothelial and epithelial cell cultures, and can be seen free within the cytoplasm,<sup>37,38</sup> within vesicles,<sup>31,39</sup> and within erythrocytes.<sup>39</sup> Motility alone, or in conjunction with other factors, may allow for the rapid translocation of cell monolayers described *in vitro*.<sup>38</sup>

## Toxins

Few organisms may be present in areas with lesions, which may be the result of toxic factors released from the spirochete or host.<sup>40, 41, 42, 43</sup> Toxic factors of leptospire include LPS,<sup>44</sup> glycolipoprotein,<sup>45</sup> peptidoglycan,<sup>46</sup> and phospholipases.<sup>47, 48</sup>

The LPS is embedded in the outer membrane,<sup>37</sup> and comprises the major surface component. However, it does not cause endotoxic effects.<sup>49</sup> Despite some structural, biochemical, and immunological similarities to gram-negative LPS, leptospiral LPS is 10 fold less toxic for animals or cells.<sup>50</sup> When procedures for endotoxin isolation from gram-negative bacteria were applied to virulent *Leptospira interrogans* serovar Icterohaemorrhagiae, injections of the extract into animals failed to produce clinical signs.<sup>51</sup> One aspect of this markedly different response may be a result of leptospiral LPS ligand specificity for Toll-like receptor-2 (TLR2) rather than TLR4 like gram-negative bacteria.<sup>52</sup>

Glycolipoprotein adheres to endothelial cells and epithelial membranes, is colocalized with antigen derived from degenerating bacteria,<sup>40</sup> and is associated with endocytosis.<sup>53</sup> The lipid portion of the leptospiral glycolipoprotein causes membrane perforation, cellular leakage, and cell death.<sup>45</sup> One mechanism of injury is through inhibition of the Na,K ATPase.<sup>54, 55, 56</sup> Application of *Leptospira* derived Na, K ATPase antagonists to peripheral blood mononuclear cells (PBMC) results in cytokine secretion.<sup>43</sup>

Leptospiral peptidoglycan causes proliferation of human peripheral blood mononuclear cells, stimulates phagocytosis, induces the metabolic burst of resting and phagocytosing leukocytes,<sup>57</sup> and induces release of TNF- $\alpha$  from human monocytes.<sup>46</sup> Pathogenic strains of *Leptospira* contain enzymes with hemolytic activity such as sphingomyelinase C<sup>58</sup> and phospholipases.<sup>47, 59</sup> Sphingomyelinase C destroys erythrocyte cell

membranes leading to hemolysis,<sup>60</sup> which may liberate iron and fatty acids.<sup>9</sup> SphH, a homolog to the sphingomyelinase C of *L. borgpetersenii* causes hemolysis through pore formation.<sup>61</sup> Some strains of *Leptospira* exhibit positive chemotaxis to hemoglobin,<sup>62</sup> but the recent demonstration of a pathway for the biosynthesis of heme<sup>63</sup> may suggest that hemolysis is more likely a means of obtaining fatty acids.

**Outer membrane proteins (OMPs).** OMPs consist of transmembrane proteins and outer membrane lipoproteins that are anchored to either the extracellular or the periplasmic side of the membrane. Lipoproteins, the most abundant proteins in spirochete outer membranes, play a role in host immunity and inflammation.<sup>64, 65</sup> Leptospire, unlike typical gram-negative species, have a paucity of outer membrane proteins, which may be a mechanism of avoiding the host immune response.<sup>66</sup> However, the scarcity of OMP's implies that those present are critical to function. A few have been characterized in detail including a porin, OmpL1,<sup>67, 66</sup> two lipoproteins, LipL36<sup>68</sup> and LipL41,<sup>69</sup> and the major outer membrane protein (MOMP) LipL32.<sup>70</sup> OmpL1, LipL41, and LipL32 are present in natural infections based on immunohistochemistry and immunoblot evidence.<sup>64</sup> OmpL1 is conserved among pathogenic species and is surface located. However, it is expressed at very low levels and is difficult to purify due to its association with LPS.<sup>66</sup>

Some OMPs exhibit the potential for immunoprotection, and all pathogenic *Leptospira* express transmembrane proteins that are less variable than serovar specific LPS. These may be useful in preparing improved vaccines.<sup>64</sup> Immunization with OmpL1, an integral outer membrane porin,<sup>66</sup> and LipL41, a lipoprotein, are protective when administered in concert.<sup>64</sup> LipL32 is the most prominent protein in the leptospiral protein profile, is expressed during *in vitro* and *in vivo*, and is conserved among pathogenic species.<sup>70</sup> The



abundance of LipL32 in the outer membrane may also make it useful as a serologic diagnostic test, since humans have been shown to have a stronger antibody response to this lipoprotein than other outer membrane proteins based on ELISA absorbance.<sup>70, 71</sup>

In vitro cultivation is associated with qualitative and quantitative changes in LPS and OMPs,<sup>72</sup> For example, LipL36 is expressed in cultured *Leptospira kirschneri* serovar Grippotyphosa, but is downregulated during mammalian infection.<sup>68</sup> LipL45, an inner membrane protein, is expressed by many low passage strains of serovar Grippotyphosa, but not in high passage strains.<sup>73</sup>

### **Pathogenesis**

The concepts of maintenance and incidental hosts are critical to understanding the pathogenesis of leptospirosis. There are different clinical implications due to infections with host-adapted and non-host-adapted species of *Leptospira*.<sup>74</sup> Maintenance or reservoir hosts serve as a source of infection, and infection persists in these animals without causing severe clinical signs. Rodents such as the wild Norway rat and albino laboratory rat are nonsymptomatic carriers of some serovars of *Leptospira*,<sup>75</sup> but depending on the serovar of *Leptospira*, many different species can serve as reservoirs. Typically, maintenance hosts do not show clinical signs, have a low serologic response, and fail to clear the organism from the kidneys. These hosts serve as long term source of infection because they excrete leptospire in their urine. Transmission between maintenance hosts is efficient. When outbreaks occur with host-adapted strains, it is a result of exposure of immunologically naïve animals.<sup>74</sup>

In incidental hosts, disease onset is acute and severe leading to organ failure and death. Often there are high titers of agglutinating antibody, and a short renal carrier state.<sup>2</sup>

Human beings are usually an incidental host that becomes infected through occupational or environmental exposure.<sup>76</sup> Incidental hosts are not important reservoirs, but direct transmission through alternative routes such as human to human transmission through breast milk have been described.<sup>8, 77</sup>

Modes of transmission are direct including venereal, transplacental, conjunctival, or oral exposure, or indirect contact with contaminated water or soil or indirect vectors.<sup>10</sup>

Leptospire enter the blood stream by epithelial invasion at the mucous membranes or entry through abraded skin after direct contact with infected urine or indirect contact with contaminated water. During a variable incubation period (3-20 days) leptospire circulate in the blood and replicate in the liver, spleen, kidneys, eyes, and other tissues. The length of the incubation period depends on the virulence, infecting dose, and the susceptibility of the host.<sup>10</sup> Agglutinating antibodies appear soon after leptospire are in the bloodstream and are associated with clearance of the leptospire from the blood. Nonspecific clinical signs are reported including fever, inappetence, vomiting, abdominal pain, diarrhea, polyuria/polydipsia, myalgia, jaundice, epistaxis, hematuria, and reproductive failure, but subclinical infections are common.<sup>78, 79</sup> It is not clear if clinical signs occur as a result of damage caused by large numbers of leptospire circulating in the blood, or due to leptospiral toxins such as lipopolysaccharide or glycolipoprotein.<sup>45</sup>

Renal colonization is requisite for shedding of organisms in the urine. Interstitial nephritis and tubular necrosis occur as a result of leptospire migration in the interstitium, renal tubules, and tubular lumina<sup>80</sup> likely compounded by liberation of toxin,<sup>81</sup> renal ischemia,<sup>82</sup> and immunologic reaction.<sup>83</sup> The primary path of leptospire from the blood into the renal tubules is between proximal convoluted tubular epithelial cells and is associated with early

interstitial edema followed by the presence of leptospire between cells.<sup>84</sup> In a hamster model of serovar Bataviae infection, lesions were detectable at 6 hours PI, and leptospire were detected within the proximal tubules at 9 hours PI.<sup>80</sup> Mild and transient glomerular involvement after initial infection has been described and is associated with C3 trapping in glomerular tufts.<sup>80</sup> Leptospire remain in kidney and eye for weeks or months after infection.

### **Serovars Studied**

Serovars common to temperate climates include Icterohaemorrhagiae, Hardjo, Pomona, Bratislava, and Canicola, while additional serovars are common to the tropics.<sup>4</sup> Traditionally, serovars Icterohaemorrhagiae and Canicola are the most prevalent in dogs, but recent clinical and epidemiologic evidence suggests that other serovars are more prevalent in canine populations in the U.S. and Canada including *Leptospira kirschneri* serovar Grippotyphosa and *Leptospira interrogans* serovars Pomona and Bratislava<sup>85-87</sup> for which dogs serve as incidental hosts.

#### **Serovar Grippotyphosa**

Serovar Grippotyphosa is commonly isolated from wild mammal carriers such as squirrels, opossums, foxes, raccoons, and skunks.<sup>2, 88, 89</sup> *L. kirschneri* serovar Grippotyphosa has been associated with severe, rapid onset renal and hepatic failure in dogs, and in the Midwest,<sup>87</sup> Georgia,<sup>88,</sup> and New York,<sup>90</sup> is the predominant serovar responsible for canine leptospirosis.

#### **Serovar Pomona**

Serovar Pomona infections in swine cause abortion, stillbirths, and neonatal deaths,<sup>90,</sup>  
<sup>91</sup> and has been isolated from cattle, horses, humans, sheep, and wildlife.<sup>92</sup> Swine,<sup>76, 90, 92</sup>

deer,<sup>74</sup> skunks, and opossums<sup>92</sup> serve as a reservoir of serovar pomona infection, but the field vole (*Microtus lagrestis*) and raccoons are thought to be the most common reservoirs in the United States.<sup>88</sup> Pomona was demonstrated to be the cause of clinical illness and death in sea lions from the coast of California after contacting contaminated surface water while on land.<sup>93</sup> The serovar Pomona isolate used in our studies is *Leptospira interrogans* serovar Pomona type kennewicki.<sup>94, 95</sup>

### **Serovar Bratislava**

*Leptospira interrogans* serovar Bratislava has been isolated from North American and European swine with reproductive failure,<sup>96</sup> and has been isolated from stillborn and neonatal swine<sup>97</sup> and tissues from slaughter.<sup>98</sup> There is a high seroprevalence of serovar Bratislava in North American horses, a presumed reservoir.<sup>74</sup> There is serologic evidence of infections in dogs,<sup>79, 99</sup> but serovar Bratislava has rarely been isolated.<sup>79, 96</sup>

### **Animal models**

A suitable system for the biological measurement of virulence attributes of a leptospiral isolate requires animals susceptible to the strains of leptospires being tested. It is difficult to study leptospirosis in laboratory mice and rats because they rapidly develop high agglutinating antibody titers after exposure to leptospires.<sup>75, 100</sup> Clinical signs only occur in rats inoculated after cyclophosphamide immunosuppression of humoral immunity.<sup>75</sup> Suitable susceptible species that have been used as laboratory animal models of leptospiral disease include hamsters (*Cricetus aureus*, *Cricetus sinensis*), guinea pigs (*Cavia cobaya*), and gerbils (*Meriones unguiculatus*, *M. shawi*, *M. crassus sacramenti*). Young guinea pigs<sup>33, 101,</sup>

<sup>102</sup> and hamsters<sup>41, 70, 103, 104</sup> are used in experimental studies and to test and maintain virulence of leptospires.<sup>105</sup>

### **Canine Leptospirosis**

The clinical entity that came to be known as canine leptospirosis was first described in 1899.<sup>106</sup> Leptospirosis should be considered as a differential diagnosis for dogs presenting with pulmonary signs, renal disease, hepatic disease, or a combination of all three.<sup>85</sup> The recognition of disease clinically is less frequent than the predicted prevalence by serologic studies.<sup>90</sup> It has been suggested that the incidence of disease may be higher than predicted by serology since infections may occur from serovars not tested in the serologic panel,<sup>107</sup> and because clinically normal dogs may shed leptospires and lack clinical signs to warrant testing.<sup>108</sup>

In the United States, canine leptospirosis has traditionally been associated with *Leptospira interrogans* serovars Canicola and Icterohaemorrhagiae. Retrospective and experimental studies have extensively documented the lesions and biochemical abnormalities associated with disease caused by serovar Canicola<sup>83, 106, 109, 110</sup> and serovar Icterohaemorrhagiae.<sup>111-114</sup> The use of vaccines containing these serovars has markedly reduced the incidence of leptospirosis in dogs.<sup>99, 115</sup> However, those vaccines do not induce cross-protective antibody to serovars not contained in the vaccine.<sup>2</sup> The diagnosis of leptospirosis has increased at North American veterinary teaching hospitals since 1983.<sup>86</sup> Several factors may be playing a role in the increased detection of leptospirosis in dogs, including increased prevalence of the disease due to the emergence of new serovars, changes in diagnostic procedures and awareness, or changes in vaccine usage.<sup>86</sup>

Leptospirosis caused by *Leptospira kirschneri* serovar Grippotyphosa<sup>78, 116, 117</sup> and *L. interrogans* serovars Pomona<sup>78, 115, 118</sup> and Bratislava<sup>79, 96, 99</sup> have emerged as an important renal and hepatic disease of dogs in North America<sup>2, 78, 85, 99</sup> and the United Kingdom.<sup>119</sup> Serovars Grippotyphosa and Pomona are reported to be the most seroprevalent.<sup>120</sup> The increased prevalence of these new serovars in dogs may be a result of entering a niche previously filled by serovars Canicola and Icterohaemorrhagiae or increasing opportunities for contact with maintenance hosts in suburban areas.<sup>2</sup> In the northern United States, there is an increased incidence in dogs from August to November when temperatures are optimal for environmental survival.<sup>85</sup> Unusually wet conditions also can cause a marked rise in case numbers over a short period of time.<sup>121</sup> Preliminary experimental studies were done with serovar Grippotyphosa, but few dogs were used and inoculation was by an unnatural route (subcutaneous or intravenous).<sup>88</sup> Serovar Grippotyphosa has been implicated as the cause of acute renal failure<sup>88</sup> and chronic active hepatitis,<sup>116</sup> and serovar Pomona was isolated from a dog with jaundice and hepatic insufficiency.<sup>118</sup>

These emerging serovars are a national concern because there has been an increase in diagnosis, vaccines have not been available that protect against the new serovars and because of the potential for zoonotic transmission.<sup>122</sup> The importance of improving control of leptospirosis in dogs is underscored by the fact that infections with serovar Icterohaemorrhagiae, the most commonly diagnosed serovar of *Leptospira* in humans,<sup>118</sup> is associated with exposure to infected dogs,<sup>74</sup> and immunized dogs have been documented as a source of zoonotic infection.<sup>123, 124</sup> More commonly, however, human beings come into contact with urine contaminated soil or water or are infected through occupational exposure with increased risk to farmers, sewer workers, miners, fisherman, and slaughterhouse

workers.<sup>11</sup> In addition, new ways of interacting with the environment such as ecotourism and outdoor sports have been the source of infection in recent human outbreaks.<sup>4, 11, 125, 126</sup>

Other serovars have been studied in dogs after experimental infection<sup>127</sup> or accidental infection in laboratory beagles.<sup>128, 129</sup> Experimental infection caused by serovar Bataviae caused severe, but variable disease with hepatic, renal, and hemorrhagic manifestations.<sup>127</sup> Accidental infection of laboratory beagles with serovar Saxkoebing was clinically inapparent, but acute hepatic and renal abnormalities with multiple hemorrhages resulted from infection with another serogroup Sejroe pathogen in that population of dogs.<sup>128</sup> An earlier report of accidental infection of laboratory beagles with serovar Sejroe described clinically inapparent infections with 59% of the dogs had interstitial nephritis and titers of 1:100 to 1:6400 without any prior indication of infection when necropsied at the end of a toxicology study.<sup>129</sup> In some areas, there is a high seroprevalence of serovar Autumnalis, but isolation and identification was not done making it unclear if serovar Autumnalis is present in dogs or if the titers are a result of serologic cross-reactivity.<sup>121</sup>

### **Host response**

**Immunology.** Leptospire interact with the host on many levels. After entering the bloodstream, virulent leptospire are rapidly phagocytosed by fixed phagocytes.<sup>130</sup> Leptospiral entry into macrophage cell lines can induce apoptosis, but entry into renal fibroblast (Vero) cell lines does not result in apoptosis.<sup>131</sup> Apoptosis of hepatocytes, however, is induced early in disease when leptospire are localized between and not within hepatocytes, which may facilitate further colonization. The role apoptosis plays in allowing further colonization of tissues requires more study.

Plasma cytokine levels are elevated in severe leptospirosis,<sup>43</sup> which are similar to classical endotoxin mediated bacterial sepsis of gram-negative organisms. Elevated acute tumor necrosis factor alpha (TNF- $\alpha$ ) levels parallel the severity of disease, whereas interleukin-10 (IL-10) levels are elevated, but not associated with the severity of disease.<sup>43</sup> Glycolipoprotein extracted from pathogenic leptospire, but not saprophytic leptospire was demonstrated to activate human peripheral blood mononuclear cells.<sup>43</sup> These cells secreted TNF- $\alpha$  and IL-10 and had a concomitant increase in expression of CD69 and HLA-DR, markers for cellular activation.<sup>43</sup> When outer membrane protein extracts are applied to cultured medullary thick ascending limb of loop of Henle (mTAL) cells, nuclear DNA binding of the NF $\kappa$ B transcription factor is induced<sup>132</sup> indicating activation of inflammatory responses.

Resistance to leptospiral infection has been shown to be primarily humorally mediated through experimental inoculations of mice and rats with cyclophosphamide, a selective blocker of humoral immunity.<sup>75, 100</sup> Treated rats had longer leptospiremic phases, higher replication rates, and greater tissue invasion than nontreated rats, which occurred during a period of absence of agglutinating antibodies relative to control rats.<sup>75</sup> In guinea pigs, increased resistance to infection was correlated with increased weight of the guinea pigs, the development of the ability to produce agglutinating antibodies, and with maturation of B-cell dependent areas of lymphoid tissue.<sup>102</sup> Lipopolysaccharide is recognized as an important antigen in immunity,<sup>37, 133, 134</sup> and the antigenic determinants of leptospiral LPS are carbohydrate.<sup>134, 133</sup> Recent bovine studies demonstrate a potent cellular immune response characterized by production of IFN- $\gamma$  by  $\gamma\delta$  T lymphocytes after vaccination.<sup>135, 136</sup> A preference toward  $\gamma\delta$  T lymphocytes also occurs in human peripheral blood mononuclear



cells when exposed to high numbers of leptospire, whereas  $\alpha\beta$  T cell expansion occurs when exposed to low numbers of leptospire.<sup>137</sup>

**Vaccination.** Reduction of exposure and immunization are critical for prevention of leptospirosis.<sup>4</sup> A traditional vaccine for leptospirosis has been available for decades and contains two serovars that have been most commonly associated with disease in dogs: *Leptospira interrogans* serovars Canicola and Icterohaemorrhagiae. The predominant immunologic reaction occurs to lipopolysaccharide (LPS) in the outer membrane of the bacteria. Immunity to leptospire is serovar specific due to differences in the LPS. Whole-cell-killed bacterins and membrane sheath preparations have been shown to be equally protective, but sheath preparations are associated with fewer adverse reactions.<sup>19</sup> Since the immune response is serovar specific, production of bacterins with traditional techniques requires adding more serovars of bacteria to the injected product. Although this seems to be effective, it also increases the possibility of adverse reactions due to leptospiral LPS or proteins in the culture media. In addition, this type of vaccine provides only short-term protection.<sup>91</sup> Dogs vaccinated with currently available vaccines with expanded serovar coverage and challenged with serovar Canicola are protected from clinical signs, but may still shed bacteria in their urine<sup>138, 139</sup> for long periods of time.<sup>123</sup>

**Histopathology.** Due to the critical role of the kidney in the lifecycle of leptospire infection and excretion renal lesions are frequent. Plasma cells within interstitial infiltrates are associated with anti-leptospiral but not anti-renal tubular antibodies.<sup>83</sup> By immunohistochemistry, leptospiral antigen can be demonstrated in intact organisms within the proximal convoluted tubules, granular deposits within macrophage cytoplasm, and as clumps within the interstitium.<sup>83, 140</sup> Severity and extension of lesions of the renal

microvasculature occur in parallel with tubular lesions suggesting the simultaneous action of a toxin on both<sup>101</sup> with exacerbation of tubular lesions by hypoxia.<sup>141</sup> Interstitial nephritis and edema are prominent in infected animals with and without renal insufficiency suggesting that additional factors play a role in renal failure.<sup>101</sup> A mixed cell infiltrate generally indicates more acute disease,<sup>142</sup> and functions in antibody production and phagocytosis.<sup>83</sup> Despite severe clinicopathologic abnormalities, infected dogs with serovars Autumnalis and Canicola did not have major histopathologic changes.<sup>110</sup>

**Ultrastructure.** Ultrastructural studies demonstrate lesions directly associated with the presence of leptospire and lesions not spatially associated with organisms. Serovar Icterohaemorrhagiae infection in guinea pigs causes intracellular edema, dilated ER, edematous microvilli, and mitochondrial changes including enlargement, clearing of the matrix, and abnormal cristae.<sup>101</sup> In infected animals, leptospire are visible in vascular and tubular lumina; intercellular spaces; and in one occasion, within an intact tubular cell.<sup>101</sup> More typically, only fragments of leptospire are present within lysosomes of the tubular epithelial cells.<sup>84</sup>

**Serum biochemical abnormalities.** Renal and hepatic damage are commonly reported in leptospirosis. Serum biochemical alterations are indicative of renal tubular injury leading to potassium secretion probably due to a decrease in proximal sodium reabsorption with collecting duct resistance partially responsible for the inability to concentrate urine.<sup>1</sup> Glucosuria occurs in some cases, likely as the result of tubular damage.<sup>78</sup> Increased urinary excretion of low molecular weight proteins results from tubular damage in leptospirosis.<sup>143</sup>

**Hematology, hemostasis, and platelets.** The most common hematologic abnormalities are mature neutrophilic leukocytosis, mild non-regenerative anemia, and

thrombocytopenia.<sup>85,99</sup> Hemorrhage is a common clinical sign in human beings and animals with leptospirosis, but the role of platelets in the mechanism of hemorrhage in leptospirosis has not been well characterized. Platelets are small, anuclear cells that circulate in the blood and function in maintaining vessel integrity by forming a platelet plug during endothelial injury. Decreased numbers of circulating platelets and altered platelet function may both play a role in the development of clinical hemorrhage. Platelet aggregation at sites of vascular injury is essential for the formation of the primary hemostatic plug and also for the development of thrombi. The initial contact of the platelet with the injured vessel wall (platelet adhesion) involves multiple adhesive substrates (von Willebrand factor, collagen) and receptors on the platelet surface (GPIb/V/IX, integrins  $\alpha_{IIb}\beta_3$  and  $\alpha_2\beta_1$ ). Physiologic platelet agonists (ADP, collagen, thrombin) work by increasing the number or ligand efficiency of adhesion receptors.<sup>144</sup> Injury to the vessel wall exposes collagen fibers in the subendothelium, which activates platelets to form a plug to prevent loss of blood. At this point, the platelets change shape and come into contact with other platelets. Granule contents are secreted and contraction occurs allowing the aggregated mass to plug the damaged site and limit blood loss.

Thrombocytopenia<sup>78, 85, 99, 121, 145</sup> and pulmonary hemorrhage are common manifestations of leptospirosis in humans.<sup>146-149</sup> However, hemorrhagic disease also occurs in the absence of thrombocytopenia.<sup>147</sup> Low numbers of circulating platelets may result from a lack of production, increased destruction, or loss. The hypothesis that thrombocytopenia and widespread endothelial damage are the cause of disseminated intravascular coagulopathy (DIC) and hemorrhage in patients with leptospirosis is no longer accepted.<sup>145, 148, 150</sup> Slightly elevated fibrin degradation products (FDP) were considered evidence for DIC in one study,<sup>80</sup>

but the occurrence of DIC has not been substantiated by other experimental studies. In one case, high titers of surface bound Ig and response to corticosteroids suggested an immune mediated pathogenesis of thrombocytopenia.<sup>145</sup> Inflammation of the vessel wall induced by leptospiral toxins has been proposed as a cause for low platelet counts in the previous studies,<sup>151</sup> but was not demonstrated or specifically investigated. Vasculitis affects primarily the capillaries of “filter” organs such as kidney, liver, and lung.<sup>11</sup> Endothelial cells participate in inflammatory responses through expression of adhesion molecules and the production of cytokines.<sup>152</sup> If platelets are functioning properly, normal hemostatic mechanisms are maintained even after platelet counts fall well below the normal reference range.

A leptospire interaction with normal integrin  $\alpha\text{IIb}\beta_3$  function could have severe consequences to normal hemostasis. Integrin  $\alpha\text{IIb}\beta_3$  complexes mediate platelet aggregation by binding fibrinogen or vWF (von Willebrand factor), protein cofactors that form bridges between adjacent platelets.<sup>153</sup> The cross linked adhesive proteins assemble platelets into an aggregate. Binding of vWF and other adhesive proteins, such as fibronectin, to integrin  $\alpha\text{IIb}\beta_3$  is mediated by the Arg-Gly-Asp (RGD) sequence, a universal mediator of cellular interactions with the extracellular matrix. GPIIb-IIIa inhibitors block aggregation and “outside in” signaling, which would lead to other events such as secretion, clot retraction, and procoagulant activity.

Platelet to spirochete binding is a feature of other diseases caused by spirochetes including relapsing fever<sup>154</sup> and Lyme disease.<sup>155, 156</sup> In relapsing fever, the pathogen, *Borrelia hermsii*, alters the conformation of integrin  $\alpha\text{IIb}\beta_3$  on resting platelets resulting in contact-

dependent activation.<sup>154</sup> *Borrelia burgdorferi*, the causative agent of Lyme disease, binds with greater affinity to activated platelets.<sup>155</sup> Spirochete to platelet binding in Lyme disease is directly associated with the ability to cause disease, i.e. those spirochetes unable to bind platelets do not cause clinical signs in animal models.<sup>155</sup>

### **Diagnosis**

Clinical diagnosis of leptospirosis can be challenging because signs are nonspecific. Nonspecific clinical signs of leptospirosis including fever, inappetence, vomiting, abdominal pain, diarrhea, polyuria/polydipsia, myalgia, jaundice, epistaxis, and hematuria may suggest disease, but are not diagnostic. Clinical pathologic changes can be variable depending on stage of infection. Diagnosis is most often initially based on clinical suspicion and confirmed later by laboratory methods.<sup>157</sup> There is no sensitive, specific, low-cost, rapid and widely available diagnostic test for leptospirosis,<sup>11</sup> so multiple methods of diagnosis must be used.

Serologic tests include the microscopic agglutination test (MAT)<sup>91,158, 159</sup> and enzyme-linked immunosorbent assay.<sup>160</sup> Diagnosis is made by a fourfold increase in paired serum samples or a single markedly elevated titer.<sup>87</sup> The titer of the infecting serovar predominates,<sup>161</sup> but multiple titers can develop during the first six weeks of clinical disease.<sup>85</sup> Serology is complicated by antibody cross-reactivity between different serovars and the presence of low-titers during acute disease.<sup>78, 88, 99</sup> Leptospiruria in the absence of MAT titers is not unusual.<sup>79</sup> Previously vaccinated dogs may have elevated titers that further complicate diagnosis, and some dogs may become infected and actively shed organisms without ever having a titer greater than 1:100.<sup>79</sup> Dogs treated early may not develop MAT titers greater than 1:100<sup>162</sup> or may seroconvert to negative after appropriate treatment.<sup>163</sup> In addition, MAT titers may not

reliably reflect the immune status against leptospiral infections.<sup>164</sup> The MAT measures primarily IgM.<sup>87</sup> IgM immunoglobulins often occur within the first week of infection and commonly reach a peak level by the second week,<sup>120</sup> but IgM and IgG titers can be demonstrated by ELISA in instances when the agglutination titer by MAT remains low.<sup>165</sup> It is advisable to confirm any positive results obtained using a commercial screening test by submitting samples to a specialized reference laboratory.<sup>157</sup>

Immunofluorescence testing,<sup>166</sup> dark field microscopy, culture, polymerase-chain-reaction assays, and histopathology with special stains (e.g. silver) can be used to identify leptospire in the tissues or body fluids of dogs. However, there are drawbacks to each of these diagnostic tests. A major disadvantage to dark-field microscopy and immunofluorescence testing is the inability to identify the infecting serovar.<sup>159</sup> Darkfield microscopy is an excellent screening tool for urine, but is of low sensitivity, and organism shedding can be intermittent.<sup>99,118</sup> Culture is the diagnostic gold standard, but leptospire are difficult to culture, may take many months to grow, and cultures are susceptible to contamination. PCR assays can be specific and sensitive, but are not widely available<sup>99,163</sup> The DNA from as few as 100 leptospire can be isolated, amplified, and detected,<sup>167</sup> but it may not be possible differentiate the causative serovar.<sup>168</sup> Silver stain is the traditional method for demonstration of spirochetes in tissue sections.<sup>169</sup> However, difficulties arise when using silver stains because of extensive reticulin staining and inability to recognize leptospiral fragments, especially if few organisms are present. Leptospire can be difficult to demonstrate in cases confirmed positive by other diagnostic methods, and silver stains cannot identify altered leptospire, leptospire fragments, or antigenic products.<sup>170</sup> Immunohistochemical methods have improved the ease with which antigen can be demonstrated in paraffin embedded tissues,<sup>41, 140, 170</sup> but may not be an

appropriate procedure for clinical cases because biopsy of severely affected organ systems would be required.

### Summary

The most common serovars of *Leptospira* associated with disease in dogs have changed to include *Leptospira kirschneri* serovar Grippotyphosa and *Leptospira interrogans* serovars Pomona and Bratislava. Data from clinical cases most commonly indicate renal and hepatic damage, but the specific clinical and pathologic manifestations caused by these emerging serovars have not been investigated in an experimental setting. Developing improved treatment and prevention techniques for this widespread zoonotic disease requires further study to better understand the course of clinical disease, biochemical abnormalities, and lesions caused by serovars Grippotyphosa, Pomona, and Bratislava.

### References

1. Yang CW, Wu MS, Pan MJ. Leptospirosis renal disease. *Nephrol Dial Transplant* 2001; 16 Suppl 5: 73-77.
2. Bolin CA. Diagnosis of leptospirosis: a reemerging disease of companion animals. *Semin Vet Med Surg (Small Anim)* 1996; 11: 166-171.
3. Levett PN. Leptospirosis. *Clin Microbiol Rev* 2001; 14: 296-326.
4. Levett PN. Leptospirosis: re-emerging or re-discovered disease? *J Med Microbiol* 1999; 48: 417-418.
5. Binder WD, Mermel LA. Leptospirosis in an urban setting: case report and review of an emerging infectious disease. *J Emerg Med* 1998; 16: 851-856.
6. Weil A. Uber eine eigentumliche, mit Milztumor, Ikterus und Nephritis emhergehende, akute Infektionskrankheit. *Deutsches Arch J Klin Med* 1886; 39: 209-232.
7. Kobayashi Y. Discovery of the causative organism of Weil's disease: historical view. *J Infect Chemother* 2001; 7: 10-15.
8. Songer JG, Thiermann AB. Leptospirosis. *J Am Vet Med Assoc* 1988; 193: 1250-1254.
9. Baranton G, Old I. The Spirochaetes: a different way of life. *Bull Inst Pasteur* 1995; 93: 63-95.
10. Michna SW. Leptospirosis. *Vet Rec* 1970; 86: 484-496.
11. Plank R, Dean D. Overview of the epidemiology, microbiology, and pathogenesis of *Leptospira* spp. in humans. *Microbes Infect* 2000; 2: 1265-1276.

12. Johnson RC, Harris VG. Differentiation of pathogenic and saprophytic leptospire. I. Growth at low temperatures. *J Bacteriol* 1967; 94: 27-31.
13. Farr RW. Leptospirosis. *Clin Infect Dis* 1995; 21: 1-6; quiz 7-8.
14. Ellinghausen HM, W.G. Nutrition of *Leptospira pomona* and growth of 13 other serotypes: Fractionation of oleic albumin complex and a medium of bovine albumin and polysorbate 80. *Am J Vet Res* 1965; 26: 45-51.
15. Johnson RC, Gary ND. Nutrition of *Leptospira pomona*. II. Fatty Acid Requirements. *J Bacteriol* 1963; 85: 976-982.
16. Johnson R, Rogers P. 5-fluorouracil as a selective agent for growth of *Leptospira*. *J Bact* 1963; 87: 422-426.
17. Brenner DJ, Kaufmann AF, Sulzer KR, et al. Further determination of DNA relatedness between serogroups and serovars in the family *Leptospiraceae* with a proposal for *Leptospira alexanderi* sp. nov. and four new *Leptospira* genomospecies. *Int J Syst Bacteriol* 1999; 49 Pt 2: 839-858.
18. Faine SA, B. Bolin, C. Perolat, P. In: *Leptospira* and Leptospirosis. Melbourne: MediSci, 1999; 272.
19. Auran NE, Johnson RC, Ritzi DM. Isolation of the outer sheath of *Leptospira* and its immunogenic properties in hamsters. *Infect Immun* 1972; 5: 968-975.
20. Ritchie AE, Ellinghausen HC. Electron microscopy of leptospire. *Journal of Bacteriology* 1965; 89: 223-233.
21. Anderson DL, Johnson RC. Electron microscopy of immune disruption of leptospire: action of complement and lysozyme. *J Bacteriol* 1968; 95: 2293-2309.
22. Zuerner RL. Physical map of chromosomal and plasmid DNA comprising the genome of *Leptospira interrogans*. *Nucleic Acids Res* 1991; 19: 4857-4860.
23. Zuerner RL, Herrmann JL, Saint Girons I. Comparison of genetic maps for two *Leptospira interrogans* serovars provides evidence for two chromosomes and intraspecies heterogeneity. *J Bacteriol* 1993; 175: 5445-5451.
24. Goldstein SF, Charon NW. Motility of the spirochete *Leptospira*. *Cell Motil Cytoskeleton* 1988; 9: 101-110.
25. Klemm P, Schembri MA. Bacterial adhesins: function and structure. *Int J Med Microbiol* 2000; 290: 27-35.
26. Merien F, Truccolo J, Baranton G, et al. Identification of a 36-kDa fibronectin-binding protein expressed by a virulent variant of *Leptospira interrogans* serovar Icterohaemorrhagiae. *FEMS Microbiol Lett* 2000; 185: 17-22.
27. Ito T, Yanagawa R. Leptospiral attachment to extracellular matrix of mouse fibroblast (L929) cells. *Vet Microbiol* 1987; 15: 89-96.
28. Ito T, Yanagawa R. Leptospiral attachment to four structural components of extracellular matrix. *Nippon Juigaku Zasshi* 1987; 49: 875-882.
29. Ballard SA, Williamson M, Adler B, et al. Interactions of virulent and avirulent leptospire with primary cultures of renal epithelial cells. *J Med Microbiol* 1986; 21: 59-67.
30. Vinh T, Faine S, Adler B. Adhesion of leptospire to mouse fibroblasts (L929) and its enhancement by specific antibody. *J Med Microbiol* 1984; 18: 73-85.
31. Thomas DD, Higbie LM. *In vitro* association of leptospire with host cells. *Infect Immun* 1990; 58: 581-585.



32. Pereira MM, Andrade J, Lacerda MD, et al. Demonstration of leptospiral antigens on tissues using monoclonal antibodies and avidin-biotin peroxidase staining. *Exp Toxicol Pathol* 1997; 49: 505-511.
33. De Brito T, Prado MJ, Negreiros VA, et al. Detection of leptospiral antigen (*L. interrogans* serovar Copenhageni serogroup Icterohaemorrhagiae) by immunoelectron microscopy in the liver and kidney of experimentally infected guinea-pigs. *Int J Exp Pathol* 1992; 73: 633-642.
34. Cinco M, Cini B, Perticarari S, et al. *Leptospira interrogans* binds to the CR3 receptor on mammalian cells. *Microb Pathog* 2002; 33: 299-305.
35. Matsunaga J, Barocchi MA, Croda J, et al. Pathogenic *Leptospira* species express surface-exposed proteins belonging to the bacterial immunoglobulin superfamily. *Mol Microbiol* 2003; 49: 929-945.
36. Cox PJ, Twigg GI. Leptospiral motility. *Nature* 1974; 250: 260-261.
37. Cinco M, Banfi E, Panfili E. Leptospiral lipopolysaccharide presence in the outer envelope: electrophoretic evidence and immunological specificity. *Zentralbl Bakteriol Mikrobiol Hyg [A]* 1988; 269: 277-283.
38. Barocchi MA, Ko AI, Reis MG, et al. Rapid translocation of polarized MDCK cell monolayers by *Leptospira interrogans*, an invasive but nonintracellular pathogen. *Infect Immun* 2002; 70: 6926-6932.
39. Miller NG, Wilson RB. *In vivo* and *in vitro* observations of *Leptospira pomona* by electron microscopy. *J Bacteriol* 1962; 84: 569-576.
40. Alves VA, Gayotto LC, Yasuda PH, et al. Leptospiral antigens (*L. interrogans* serogroup ictero-haemorrhagiae) in the kidney of experimentally infected guinea pigs and their relation to the pathogenesis of the renal injury. *Exp Pathol* 1991; 42: 81-93.
41. Barnett JK, Barnett D, Bolin CA, et al. Expression and distribution of leptospiral outer membrane components during renal infection of hamsters. *Infect Immun* 1999; 67: 853-861.
42. De Brito T, Bohm GM, Yasuda PH. Vascular damage in acute experimental leptospirosis of the guinea-pig. *J Pathol* 1979; 128: 177-182.
43. Diamant D, Brunialti MK, Romero EC, et al. Peripheral blood mononuclear cell activation induced by *Leptospira interrogans* glycolipoprotein. *Infect Immun* 2002; 70: 1677-1683.
44. Isogai E, Isogai H, Kurebayashi Y, et al. Biological activities of leptospiral lipopolysaccharide. *Zentralbl Bakteriol Mikrobiol Hyg [A]* 1986; 261: 53-64.
45. Vinh T, Adler B, Faine S. Glycolipoprotein cytotoxin from *Leptospira interrogans* serovar Copenhageni. *J Gen Microbiol* 1986; 132: 111-123.
46. Cinco M, Vecile E, Murgia R, et al. *Leptospira interrogans* and *Leptospira* peptidoglycans induce the release of tumor necrosis factor alpha from human monocytes. *FEMS Microbiol Lett* 1996; 138: 211-214.
47. Volina EG, Levina LF, Soboleva GL. Phospholipase activity and virulence of pathogenic leptospirae. *J Hyg Epidemiol Microbiol Immunol* 1986; 30: 163-169.
48. Yanagihara Y, Taniyama T, Misaki H, et al. Phospholipases of *Leptospira*. I. Presence of phospholipase A1 and lysophospholipase in *Leptospira biflexa*. *Microbiol Immunol* 1984; 28: 747-756.

49. Vinh T, Adler B, Faine S. Ultrastructure and chemical composition of lipopolysaccharide extracted from *Leptospira interrogans* serovar Copenhageni. *J Gen Microbiol* 1986; 132 ( Pt 1): 103-109.
50. Zuerner R, Haake D, Adler B, et al. Technological advances in the molecular biology of *Leptospira*. *J Mol Microbiol Biotechnol* 2000; 2: 455-462.
51. Arian VS, Green, J. The Pathogenesis of Leptospirosis: Toxin Production by *Leptospira icterohaemorrhagiae*. *Am J Vet Res* 1964; 26: 836-843.
52. Werts C, Tapping RI, Mathison JC, et al. Leptospiral lipopolysaccharide activates cells through a TLR2-dependent mechanism. *Nat Immunol* 2001; 2: 346-352.
53. Bao L, Dai BM. [Endocytosis and cytotoxin effect induced by the attachment of the glycolipoprotein of leptospire to vascular endothelial cell in culture]. *Hua Xi Yi Ke Da Xue Xue Bao* 1989; 20: 115-118.
54. Younes-Ibrahim M, Burth P, Faria MV, et al. Inhibition of Na,K-ATPase by an endotoxin extracted from *Leptospira interrogans*: a possible mechanism for the physiopathology of leptospirosis. *C R Acad Sci III* 1995; 318: 619-625.
55. Younes-Ibrahim M, Burth P, Castro-Faria M, et al. Effect of *Leptospira interrogans* endotoxin on renal tubular Na,K-ATPase and H,K-ATPase activities. *Ann N Y Acad Sci* 1997; 834: 684-686.
56. Burth P, Younes-Ibrahim M, Gonzalez FH, et al. Purification and characterization of a Na<sup>+</sup>, K<sup>+</sup> ATPase inhibitor found in an endotoxin of *Leptospira interrogans*. *Infect Immun* 1997; 65: 1557-1560.
57. Cinco M, Perticarari S, Presani G, et al. Biological activity of a peptidoglycan extracted from *Leptospira interrogans*: in vitro studies. *J Gen Microbiol* 1993; 139 ( Pt 12): 2959-2964.
58. Bernheimer AW, Bey RF. Copurification of *Leptospira interrogans* serovar Pomona hemolysin and sphingomyelinase C. *Infect Immun* 1986; 54: 262-264.
59. Kasarov LB. Degradation of the erythrocyte phospholipids and haemolysis of the erythrocytes of different animal species by leptospirae. *J Med Microbiol* 1970; 3: 29-37.
60. del Real G, Segers RP, van der Zeijst BA, et al. Cloning of a hemolysin gene from *Leptospira interrogans* serovar Hardjo. *Infect Immun* 1989; 57: 2588-2590.
61. Lee SH, Kim KA, Park YG, et al. Identification and partial characterization of a novel hemolysin from *Leptospira interrogans* serovar Lai. *Gene* 2000; 254: 19-28.
62. Yuri K, Takamoto Y, Okada M, et al. Chemotaxis of leptospire to hemoglobin in relation to virulence. *Infect Immun* 1993; 61: 2270-2272.
63. Guegan R, Camadro JM, Saint Girons I, et al. *Leptospira* spp. possess a complete haem biosynthetic pathway and are able to use exogenous haem sources. *Mol Microbiol* 2003; 49: 745-754.
64. Haake DA, Mazel MK, McCoy AM, et al. Leptospiral outer membrane proteins OmpL1 and LipL41 exhibit synergistic immunoprotection. *Infect Immun* 1999; 67: 6572-6582.
65. Haake DA. Spirochaetal lipoproteins and pathogenesis. *Microbiology* 2000; 146: 1491-1504.
66. Shang ES, Exner MM, Summers TA, et al. The rare outer membrane protein, OmpL1, of pathogenic *Leptospira* species is a heat-modifiable porin. *Infect Immun* 1995; 63: 3174-3181.

67. Haake DA, Champion CI, Martinich C, et al. Molecular cloning and sequence analysis of the gene encoding OmpL1, a transmembrane outer membrane protein of pathogenic *Leptospira* spp. *J Bacteriol* 1993; 175: 4225-4234.
68. Haake DA, Martinich C, Summers TA, et al. Characterization of leptospiral outer membrane lipoprotein LipL36: downregulation associated with late-log-phase growth and mammalian infection. *Infect Immun* 1998; 66: 1579-1587.
69. Shang ES, Summers TA, Haake DA. Molecular cloning and sequence analysis of the gene encoding LipL41, a surface-exposed lipoprotein of pathogenic *Leptospira* species. *Infect Immun* 1996; 64: 2322-2330.
70. Haake DA, Chao G, Zuerner RL, et al. The leptospiral major outer membrane protein LipL32 is a lipoprotein expressed during mammalian infection. *Infect Immun* 2000; 68: 2276-2285.
71. Guerreiro H, Croda J, Flannery B, et al. Leptospiral proteins recognized during the humoral immune response to leptospirosis in humans. *Infect Immun* 2001; 69: 4958-4968.
72. Haake DA, Walker EM, Blanco DR, et al. Changes in the surface of *Leptospira interrogans* serovar Grippotyphosa during in vitro cultivation. *Infect Immun* 1991; 59: 1131-1140.
73. Matsunaga J, Young TA, Barnett JK, et al. Novel 45-kilodalton leptospiral protein that is processed to a 31-kilodalton growth-phase-regulated peripheral membrane protein. *Infect Immun* 2002; 70: 323-334.
74. Heath SE, Johnson R. Leptospirosis. *J Am Vet Med Assoc* 1994; 205: 1518-1523.
75. Thiermann AB. Effect of cyclophosphamide treatment on clinical and serologic response of rats to infection with *Leptospira interrogans* serovar Icterohaemorrhagiae. *Am J Vet Res* 1980; 41: 1655-1658.
76. Campagnolo ER, Warwick MC, Marx HL, Jr., et al. Analysis of the 1998 outbreak of leptospirosis in Missouri in humans exposed to infected swine. *J Am Vet Med Assoc* 2000; 216: 676-682.
77. Bolin CA, Koellner P. Human-to-human transmission of *Leptospira interrogans* by milk. *J Infect Dis* 1988; 158: 246-247.
78. Rentko VT, Clark N, Ross LA, et al. Canine leptospirosis. A retrospective study of 17 cases. *J Vet Intern Med* 1992; 6: 235-244.
79. van den Broek AHM, Thrusfield MV, Dobie GR, et al. A serological and bacteriological survey of leptospiral infection in dogs in Edinburgh and Glasgow. *J Small An Pract* 1991; 32: 118-124.
80. Sitprija V, Pipatanagul V, Mertowidjojo K, et al. Pathogenesis of renal disease in leptospirosis: Clinical and experimental studies. *Kidney Int* 1980; 17: 827-836.
81. Miller NG, Allen JE, Wilson RB. The pathogenesis of hemorrhage in the lung of the hamster during acute leptospirosis. *Med Microbiol Immunol* 1974; 160: 269-278.
82. De Brito T, Freymuller E, Hoshino S, et al. Pathology of the kidney and liver in the experimental leptospirosis of the guinea-pig. A light and electron microscopy study. *Virchows Arch Pathol Anat Physiol Klin Med* 1966; 341: 64-78.
83. Morrison WI, Wright NG. Canine leptospirosis: an immunopathological study of interstitial nephritis due to *Leptospira canicola*. *J Pathol* 1976; 120: 83-89.
84. Marshall RB. The route of entry of leptospires into the kidney tubule. *J Med Microbiol* 1976; 9: 149-152.

85. Birnbaum N, Barr SC, Center SA, et al. Naturally acquired leptospirosis in 36 dogs: serological and clinicopathological features. *J Small Anim Pract* 1998; 39: 231-236.
86. Ward MP, Glickman LT, Guptill LF. Prevalence of and risk factors for leptospirosis among dogs in the United States and Canada: 677 cases (1970-1998). *J Am Vet Med Assoc* 2002; 220: 53-58.
87. Boutilier P, Carr A, Schulman RL. Leptospirosis in dogs: a serologic survey and case series 1996 to 2001. *Vet Ther* 2003; 4: 178-187.
88. Brown CA, Roberts AW, Miller MA, et al. *Leptospira interrogans* serovar grippotyphosa infection in dogs. *J Am Vet Med Assoc* 1996; 209: 1265-1267.
89. Thiermann AB. The Norway rat as a selective chronic carrier of *Leptospira icterohaemorrhagiae*. *J Wildl Dis* 1981; 17: 39-43.
90. Hanson LE. Leptospirosis in domestic animals: the public health perspective. *J Am Vet Med Assoc* 1982; 181: 1505-1509.
91. Thiermann AB. Leptospirosis: current developments and trends. *J Am Vet Med Assoc* 1984; 184: 722-725.
92. Bolin CA, Zuerner RL. Correlation between DNA restriction fragment length polymorphisms in *Leptospira interrogans* serovar Pomona type kennewicki and host animal source. *J Clin Microbiol* 1996; 34: 424-425.
93. McIlhattan TJ, Martin JW, Wagner RJ, et al. Isolation of *Leptospira pomona* from a naturally infected California sea lion, Sonoma County, California. *J Wildl Dis* 1971; 7: 195-197.
94. Thiermann A, McClellan R, Hill H. Improved techniques for the isolation of leptospires from swine abortion cases, in *Proceedings. 27th Annual Proceedings, Amer. Assn. Veterinary Laboratory Diagnosticians* 1984; 233-244.
95. Thiermann AB, Handsaker AL, Moseley SL, et al. New method for classification of leptospiral isolates belonging to serogroup pomona by restriction endonuclease analysis: serovar kennewicki. *J Clin Microbiol* 1985; 21: 585-587.
96. Nielsen JN, Cochran GK, Cassells JA, et al. *Leptospira interrogans* serovar bratislava infection in two dogs [see comments]. *J Am Vet Med Assoc* 1991; 199: 351-352.
97. Bolin CA, Cassells JA. Isolation of *Leptospira interrogans* serovar bratislava from stillborn and weak pigs in Iowa. *J Am Vet Med Assoc* 1990; 196: 1601-1604.
98. Ellis WA, Thiermann AB. Isolation of *Leptospira interrogans* serovar bratislava from sows in Iowa. *Am J Vet Res* 1986; 47: 1458-1460.
99. Adin CA, Cowgill LD. Treatment and outcome of dogs with leptospirosis: 36 cases (1990-1998). *J Am Vet Med Assoc* 2000; 216: 371-375.
100. Adler B, Faine S. Susceptibility of mice treated with cyclophosphamide to lethal infection with *Leptospira interrogans* serovar pomona. *Infect Immun* 1976; 14: 703-708.
101. Davila de Arriaga AJ, Rocha AS, Yasuda PH, et al. Morpho-functional patterns of kidney injury in the experimental leptospirosis of the guinea-pig (*L. icterohaemorrhagiae*). *J Pathol* 1982; 138: 145-161.
102. Adler B, Faine S, Muller HK, et al. Maturation of humoral immune response determines the susceptibility of guinea-pigs to leptospirosis. *Pathology* 1980; 12: 529-538.
103. Thompson JC, Manktelow BW. Pathogenesis of renal lesions in haemoglobinaemic and non-haemoglobinaemic leptospirosis. *J Comp Pathol* 1989; 101: 201-214.

104. Alt DP, Bolin CA. Preliminary evaluation of antimicrobial agents for treatment of *Leptospira interrogans* serovar pomona infection in hamsters and swine. *Am J Vet Res* 1996; 57: 59-62.
105. Chandrasekaran S. Review on human leptospirosis. *Indian J Med Sci* 1999; 53: 291-298.
106. McIntyre WIM, Montgomery GL. Renal Lesions in *Leptospira canicola* Infection in Dogs. *J Pathol Bact* 1952; 64: 145-160.
107. Sasaki DM. Questions stated prevalence of leptospirosis in dogs. *J Am Vet Med Assoc* 2002; 220: 1452; author reply 1452-1453.
108. Harkin KR, Roshto YM, Sullivan JT, et al. Comparison of polymerase chain reaction assay, bacteriologic culture, and serologic testing in assessment of prevalence of urinary shedding of leptospires in dogs. *J Am Vet Med Assoc* 2003; 222: 1230-1233.
109. Taylor PL, Hanson LE, Simon J. Serologic, pathologic, and immunologic features of experimentally induced leptospiral nephritis in dogs. *Am J Vet Res* 1970; 31: 1033-1049.
110. Saravanan R, Rajendran P, Garajan SP. Clinical, bacteriologic and histopathologic studies on induced leptospirosis in stray dog pups. *Indian J Pathol Microbiol* 1999; 42: 463-469.
111. Monlux W. Leptospirosis. III. The clinical pathology of canine leptospirosis. *Cornell Vet* 1948; 38: 109-121.
112. Monlux W. Leptospirosis. IV. The pathology of canine leptospirosis. *Cornell Vet* 1948; 38: 199-208.
113. Low DG, Hiatt CW, Gleiser CA, et al. Experimental Canine Leptospirosis. I. *Leptospira icterohemorrhagiae* infections in immature dogs. *J Infect Dis* 1956; 98: 249-259.
114. Navarro CE, Kociba GJ, Kowalski JJ. Serum biochemical changes in dogs with experimental *Leptospira interrogans* serovar icterohaemorrhagiae infection. *Am J Vet Res* 1981; 42: 1125-1129.
115. Kalin M, Devaux C, DiFruscia R, et al. Three cases of canine leptospirosis in Quebec. *Can Vet J* 1999; 40: 187-191.
116. Bishop L, Strandberg JD, Adams RJ, et al. Chronic active hepatitis in dogs associated with leptospires. *Am J Vet Res* 1979; 40: 839-844.
117. Cole JR, Jr., Sangster LT, Sulzer CR, et al. Infections with *Encephalitozoon cuniculi* and *Leptospira interrogans*, serovars grippotyphosa and ballum, in a kennel of foxhounds. *J Am Vet Med Assoc* 1982; 180: 435-437.
118. Prescott JF, Ferrier RL, Nicholson VM, et al. Is canine leptospirosis underdiagnosed in southern Ontario? A case report and serological survey. *Can Vet J* 1991; 32: 481-486.
119. Thomas S. Leptospirosis apparently due to *Leptospira bratislava* in a dog. *Vet Rec* 1980; 106: 178-179.
120. Ribotta M, Fortin M, Higgins R, et al. Canine leptospirosis: serology. *Can Vet J* 2000; 41: 494-495.
121. Prescott JF, McEwen B, Taylor J, et al. Resurgence of leptospirosis in dogs in Ontario: recent findings. *Can Vet J* 2002; 43: 955-961.
122. Leptospirosis cases rising in United States. *JAVMA* 1998; 212: 472.

123. Feigin RD, Lobes LA, Jr., Anderson D, et al. Human leptospirosis from immunized dogs. *Ann Intern Med* 1973; 79: 777-785.
124. Fraser DW, Glosser JW, Francis DP, et al. Leptospirosis caused by serotype Fort-Bragg. A suburban outbreak. *Ann Intern Med* 1973; 79: 786-789.
125. MMWR. Update: leptospirosis and unexplained acute febrile illness among athletes participating in triathlons--Illinois and Wisconsin, 1998. *MMWR Morb Mortal Wkly Rep* 1998; 47: 673-676.
126. Sejvar J, Bancroft E, Winthrop K, et al. Leptospirosis in "Eco-Challenge" athletes, Malaysian Borneo, 2000. *Emerg Infect Dis* 2003; 9: 702-707.
127. Keenan KP, Alexander AD, Montgomery CA, Jr. Pathogenesis of experimental *Leptospira interrogans*, serovar bataviae, infection in the dog: microbiological, clinical, hematologic, and biochemical studies. *Am J Vet Res* 1978; 39: 449-454.
128. Ruhl-Fehlert CI, Brem S, Feller W, et al. Clinical, microbiological and pathological observations in laboratory beagle dogs infected with leptospire of the serogroup Sejroe. *Exp Toxicol Pathol* 2000; 52: 201-207.
129. Scanziani E, Crippa L, Giusti AM, et al. *Leptospira interrogans* serovar sejroe infection in a group of laboratory dogs. *Lab Anim* 1995; 29: 300-306.
130. Faine S. Reticuloendothelial phagocytosis of virulent leptospire. *Am J Vet Res* 1964; 25: 830-835.
131. Merien F, Baranton G, Perolat P. Invasion of Vero cells and induction of apoptosis in macrophages by pathogenic *Leptospira interrogans* are correlated with virulence. *Infect Immun* 1997; 65: 729-738.
132. Yang CW, Wu MS, Pan MJ, et al. Leptospira outer membrane protein activates NF-kappaB and downstream genes expressed in medullary thick ascending limb cells. *J Am Soc Nephrol* 2000; 11: 2017-2026.
133. Jost BH, Adler B, Vinh T, et al. A monoclonal antibody reacting with a determinant on leptospiral lipopolysaccharide protects guinea pigs against leptospirosis. *J Med Microbiol* 1986; 22: 269-275.
134. Vinh T, Faine S, Handley CJ, et al. Immunochemical studies of opsonic epitopes of the lipopolysaccharide of *Leptospira interrogans* serovar Hardjo. *FEMS Immunol Med Microbiol* 1994; 8: 99-107.
135. Naiman BM, Alt D, Bolin CA, et al. Protective killed *Leptospira borgpetersenii* vaccine induces potent Th1 immunity comprising responses by CD4 and gammadelta T lymphocytes. *Infect Immun* 2001; 69: 7550-7558.
136. Baldwin CL, Sathiyaseelan T, Naiman B, et al. Activation of bovine peripheral blood gamma delta T cells for cell division and IFN-gamma production. *Vet Immunol Immunopathol* 2002; 87: 251-259.
137. Klimpel GR, Matthias MA, Vinetz JM. *Leptospira interrogans* activation of human peripheral blood mononuclear cells: preferential expansion of TCR gammadelta(+) T cells vs TCR alphabeta(+) T cells. *J Immunol* 2003; 171: 1447-1455.
138. Andre-Fontaine G, Branger C, Gray AW, et al. Comparison of the efficacy of three commercial bacterins in preventing canine leptospirosis. *Vet Rec* 2003; 153: 165-169.
139. Klaasen HL, Molkenboer MJ, Vrijenhoek MP, et al. Duration of immunity in dogs vaccinated against leptospirosis with a bivalent inactivated vaccine. *Vet Microbiol* 2003; 95: 121-132.

140. Wild C, Greenlee J, Bolin C, et al. An improved immunohistochemical diagnostic technique for canine leptospirosis using anti-leptospiral antibodies on renal tissue. *J Vet Diagn Invest* 2002; 14: 20-24.
141. de Brito T. On the pathogenesis of the hepatic and renal lesions in leptospirosis. *Rev Inst Med Trop Sao Paulo* 1968; 10: 237-241.
142. Sterling CR, Thiermann AB. Urban rats as chronic carriers of leptospirosis: an ultrastructural investigation. *Vet Pathol* 1981; 18: 628-637.
143. Zaragoza C, Barrera R, Centeno F, et al. Characterization of renal damage in canine leptospirosis by sodium dodecyl sulphate-polyacrylamide gel electrophoresis (SDS-PAGE) and Western blotting of the urinary proteins. *J Comp Pathol* 2003; 129: 169-178.
144. Bellavite P, Andrioli G, Guzzo P, et al. A colorimetric method for the measurement of platelet adhesion in microtiter plates. *Anal Biochem* 1994; 216: 444-450.
145. Davenport A, Rugman FP, Desmond MJ, et al. Is thrombocytopenia seen in patients with leptospirosis immunologically mediated? *J Clin Pathol* 1989; 42: 439-440.
146. Nicodemo AC, Medeiros N, del Negro G, et al. [Hematologic changes in leptospirosis]. *Rev Inst Med Trop Sao Paulo* 1989; 31: 71-79.
147. Nicodemo AC, Del Negro G, Amato Neto V. Thrombocytopenia and leptospirosis. *Rev Inst Med Trop Sao Paulo* 1990; 32: 252-259.
148. Nicodemo AC, Duarte MI, Alves VA, et al. Lung lesions in human leptospirosis: microscopic, immunohistochemical, and ultrastructural features related to thrombocytopenia. *Am J Trop Med Hyg* 1997; 56: 181-187.
149. Im JG, Yeon KM, Han MC, et al. Leptospirosis of the lung: radiographic findings in 58 patients. *AJR Am J Roentgenol* 1989; 152: 955-959.
150. Edwards CN, Nicholson GD, Hassell TA, et al. Thrombocytopenia in leptospirosis: the absence of evidence for disseminated intravascular coagulation. *Am J Trop Med Hyg* 1986; 35: 352-354.
151. van den Ingh TS, Hartman EG. Pathology of acute *Leptospira interrogans* serotype icterohaemorrhagiae infection in the Syrian hamster. *Vet Microbiol* 1986; 12: 367-376.
152. Mantovani A, Dejana E. Cytokines as communication signals between leukocytes and endothelial cells. *Immunol Today* 1989; 10: 370-375.
153. Nurden AT, Poujol C, Durrieu-Jais C, et al. Platelet glycoprotein IIb/IIIa inhibitors: basic and clinical aspects. *Arterioscler Thromb Vasc Biol* 1999; 19: 2835-2840.
154. Alugupalli KR, Michelson AD, Barnard MR, et al. Platelet activation by a relapsing fever spirochaete results in enhanced bacterium-platelet interaction via integrin alphaIIb beta3 activation. *Mol Microbiol* 2001; 39: 330-340.
155. Coburn J, Barthold SW, Leong JM. Diverse Lyme disease spirochetes bind integrin alpha IIb beta 3 on human platelets. *Infect Immun* 1994; 62: 5559-5567.
156. Coburn J, Leong JM, Erban JK. Integrin alpha IIb beta 3 mediates binding of the Lyme disease agent *Borrelia burgdorferi* to human platelets. *Proc Natl Acad Sci U S A* 1993; 90: 7059-7063.
157. Zochowski WJ, Palmer MF, Coleman TJ. An evaluation of three commercial kits for use as screening methods for the detection of leptospiral antibodies in the UK. *J Clin Pathol* 2001; 54: 25-30.

158. Cole JR, Sulzer CR, Pursell AR. Improved microtechnique for the leptospiral microscopic agglutination test. *Appl Microbiol* 1973; 25: 976-980.
159. Bolin CA, Zuerner RL, Trueba G. Comparison of three techniques to detect *Leptospira interrogans* serovar hardjo type hardjo-bovis in bovine urine. *Am J Vet Res* 1989; 50: 1001-1003.
160. Ribotta MJ, Higgins R, Gottschalk M, et al. Development of an indirect enzyme-linked immunosorbent assay for the detection of leptospiral antibodies in dogs. *Can J Vet Res* 2000; 64: 32-37.
161. Scanziani E, Calcaterra S, Tagliabue S, et al. Serological findings in cases of acute Leptospirosis in the dog. *J Small Anim Pract* 1994; 35: 257-260.
162. Levitan D. Long Island canine renal/hepatic syndrome is likely due to leptospirosis. *Veterinary News/NYS* 1996; 61: 3-4.
163. Harkin KR, Gartrell CL. Canine Leptospirosis in New Jersey and Michigan: 17 Cases (1990-1995). *J Am Anim Hosp Assoc* 1996; 32: 495-501.
164. Steger-Lieb AG, B. Nicolet, J. Gaschen, F. Eine Alte Krankheit mit neuem Gesicht: Die Hundeleptospirose verliert nicht an Aktualitat (An old disease with a new face: canine leptospirosis does not lose its relevance). *Schweizer Archiv fur Tierheilkunde* 1999; 141: 499-507.
165. Hartman EG, van den Ingh TS, Rothuizen J. Clinical, pathological and serological features of spontaneous canine leptospirosis. An evaluation of the IgM- and IgG-specific ELISA. *Vet Immunol Immunopathol* 1986; 13: 261-271.
166. Coffin DL, Maestrone G. Detection of Leptospire by Fluorescent Antibody. *Am J Vet Res* 1962; 23: 159-164.
167. Veloso IF, Lopes MT, Salas CE, et al. A comparison of three DNA extractive procedures with *Leptospira* for polymerase chain reaction analysis. *Mem Inst Oswaldo Cruz* 2000; 95: 339-343.
168. Harkin KR, Roshto YM, Sullivan JT. Clinical application of a polymerase chain reaction assay for diagnosis of leptospirosis in dogs. *J Am Vet Med Assoc* 2003; 222: 1224-1229.
169. Churukian CJ, Schenk EA. A Warthin-Starry method for spirochetes and bacteria using a microwave oven. *J Histotechnol* 1988; 11: 149-151.
170. Alves VA, Vianna MR, Yasuda PH, et al. Detection of leptospiral antigen in the human liver and kidney using an immunoperoxidase staining procedure. *J Pathol* 1987; 151: 125-131.



**CHAPTER 2. CLINICAL AND PATHOLOGIC COMPARISON OF  
ACUTE CANINE LEPTOSPIROSIS CAUSED BY TWO STRAINS OF  
*LEPTOSPIRA KIRSCHNERI* SEROVAR GRIPPOTYPHOSA**

A manuscript submitted to *The American Journal of Veterinary Research*

Justin J. Greenlee, DVM; Carole A. Bolin, DVM, PhD; David P. Alt, DVM, PhD; Norman F.

Cheville, DVM, PhD, DACVP; Claire B. Andreasen, DVM, PhD, DACVP

From the Department of Veterinary Pathology, College of Veterinary Medicine, Iowa State University, Ames, IA (Greenlee, Cheville, Andreasen), and the Bacterial Diseases of Livestock Research Unit, National Animal Disease Center, Agricultural Research Service, USDA, Ames, IA (Bolin, Alt)

\*Dr. Bolin's current address is Diagnostic Center for Population and Animal Health, College of Veterinary Medicine, Michigan State University, East Lansing, MI 48824

**ABSTRACT**

**Objective**—The purpose of this experiment was to develop a model of acute canine leptospirosis caused by *Leptospira kirschneri* serovar Grippotyphosa.

**Animals**—31 nine-week-old, female beagle dogs.

**Procedure**—Beagles were randomly assigned to challenge or control groups. Challenge groups were inoculated on three successive days by conjunctival instillation of  $5 \times 10^7$  cells of either *Leptospira kirschneri* serovar Grippotyphosa strain 82 (n=12) or serovar Grippotyphosa strain RM 52 (n=14); control dogs (n=5) were similarly inoculated with sterile leptospiral culture media. Clinical signs, clinical pathological parameters, anti-

leptospiral antibody titers, and presence of leptospire in tissues and body fluids were evaluated after challenge. Dogs were euthanized and necropsies were done on days 7, 14, 22, and 28 post-inoculation or as required because of severe illness.

**Results**— In dogs infected with serovar Grippotyphosa, clinical signs included conjunctivitis, lethargy, diarrhea, dehydration, vomiting, and icterus. Consistent clinical pathologic alterations included azotemia, hyperphosphatemia, increased anion gap, hyperbilirubinemia, and increased alkaline phosphatase. Leptospire were cultured from kidney (11/12), urine (6/9), aqueous humor (9/12), blood (12/12), and liver (12/12) of dogs inoculated with serovar Grippotyphosa strain 82. Only three dogs became infected with serovar Grippotyphosa strain RM52. Histologic lesions in infected dogs included interstitial nephritis, renal tubular degeneration and necrosis, pulmonary hemorrhage, and hepatic edema and perivasculitis.

**Conclusions and Clinical Relevance**—Conjunctival exposure to *L. kirschneri* serovar Grippotyphosa strain 82 resulted in acute leptospirosis in all inoculated dogs, but only 3/14 (21%) of RM52 inoculated dogs became acutely ill. A model of infection by *L. kirschneri* serovar Grippotyphosa is described and will be used to further explore the pathogenesis and prevention of canine leptospirosis.

Key words: Leptospira, kidneys, hepatic disease, clinical pathology-general, zoonotic disease

## INTRODUCTION

Leptospirosis, one of the most widespread zoonoses, is a re-emerging disease of dogs.<sup>1</sup> The diagnosis of canine leptospirosis in the United States and Canada significantly increased between 1983 and 1998.<sup>2</sup> In the United States, leptospirosis in dogs has traditionally been

associated with *Leptospira interrogans* serovars Canicola and Icterohaemorrhagiae. Experimental disease caused by serovars Canicola and Icterohaemorrhagiae has been described,<sup>3-10</sup> and the use of vaccines containing these serovars has markedly reduced the incidence of disease caused by them.<sup>3,4</sup> Until recently, vaccines have been available to protect against only those serovars. In the past 10 years, increasing numbers of cases of canine leptospirosis have been described with isolation or serologic evidence to support the involvement of *L. kirschneri* serovar Grippotyphosa and *L. interrogans* serovars Bratislava and Pomona.<sup>1,2,3</sup> Features of disease caused by these serovars such as time course, lesions, and biochemical abnormalities that may be serovar specific have not been well identified because of the paucity of experimental studies and the inability to determine the time of exposure in clinical cases.

Literature concerning experimental investigation of the course of disease, lesions, and confirmation of infection by serovars Grippotyphosa, Bratislava, and Pomona in dogs is sparse<sup>5,6</sup> despite the emergence of these serovars as important causes of renal and hepatic disease of dogs in North America.<sup>1,3,7,8</sup> To better understand the progression of clinical signs and clinicopathologic abnormalities in the course of disease with these emerging serovars, experimental studies are needed. The purpose of this study was to inoculate dogs with *L. kirschneri* serovar Grippotyphosa under controlled conditions and document clinical signs, changes in CBC and biochemistry profiles, and gross and histopathologic lesions at necropsy.

## **MATERIALS AND METHODS**

**Dogs**—All animal experiments were approved by the Iowa State University Committee on Animal Care. Thirty-one nine-week-old purpose-bred female beagle pups that

lacked detectable antibodies to serovar Grippityphosa by the microscopic agglutination test<sup>9</sup> were used. For the duration of the experiment, animals were housed two per cage in temperature-controlled rooms in the Iowa State University BL-2 Animal Holding Facility. Separate rooms were used for control, strain RM52 inoculated, and strain 82 inoculated dogs, respectively. Dogs were fed a high quality commercial dry ration. Food and water were available at all times and freshened twice daily. Complete blood counts (CBC), serum biochemistry panels, and urinalyses were performed on each dog during the acclimation period. No abnormalities were noted. The dogs were observed for clinical signs and body temperatures were recorded twice daily throughout the experiment.

***Leptospira strains***—Two strains of *L. kirschneri* serovar Grippityphosa were used. Serovar Grippityphosa strain RM52 was isolated at the USDA/ARS-National Animal Disease Center from tissues submitted to the Veterinary Diagnostic Laboratory at Iowa State University during an outbreak of swine abortion in 1983.<sup>10, 11</sup> To enhance virulence attributes, leptospire were passaged through hamsters<sup>12</sup> and reisolated. Hamsters were housed at the National Animal Disease Center. Intraperitoneal inoculations of consisted of 10<sup>6</sup> organisms. Inoculum was cultured in 80/40 semisolid media<sup>14</sup> from liver homogenate of a hamster with clinical signs. Serovar Grippityphosa strain 82 was isolated at the National Animal Disease Center from the urine of a dog that presented to the Veterinary Teaching Hospital at Iowa State University in 1992 with polyuria and polydipsia as the presenting complaint. This dog had mild azotemia, hypercalcemia, isosthenuria (SG=1.008), a titer of 1:1600 for serovar Grippityphosa, and detection of leptospire in urine by immunofluorescence. Hamster passage also was done for this isolate. Inoculum was

prepared from cultured liver homogenate from a hamster with clinical signs after intraperitoneal inoculation with  $10^6$  strain 82 organisms.

**Experimental design**—All inoculations occurred via conjunctival instillation. The inoculum consisted of  $5 \times 10^7$  leptospire in 500  $\mu$ l of 80/40 semisolid leptospiral culture medium.<sup>13</sup> Two hundred fifty  $\mu$ l was placed onto the corneal surface of each eye of each dog and allowed to run onto the conjunctiva. This procedure was repeated once daily for three days. Dogs 1-5 served as controls and were inoculated with an equal volume of sterile culture media. Dogs 6-17 were inoculated with serovar Grippotyphosa strain 82. Dogs 18-31 were inoculated with serovar Grippotyphosa strain RM52. Inoculum was prepared as previously described.<sup>10</sup>

**Necropsy and sample collection**— Blood samples for complete blood counts and biochemistry profiles including sodium, potassium, chloride, total  $\text{CO}_2$  ( $\text{TCO}_2$ ), calcium, phosphorus, blood urea nitrogen, creatinine, glucose, total protein, albumin, alanine aminotransferase (ALT), alkaline phosphatase (ALP),  $\gamma$ -glutamyltransferase (GGT), creatine kinase (CK), direct bilirubin (Dbili), total bilirubin (Tbili), and anion gap were taken pre-inoculation and scheduled for days 7, 14, 22, and 28 post-inoculation. If animals were necropsied on alternate days, appropriate samples were collected at that time. Necropsy values of serum biochemical assays of infected dogs were compared to baseline values using a paired T-test.

Euthanasia and necropsies were scheduled for days 7, 14, 22, and 28 post-inoculation (PI). Dogs were euthanatized immediately if dogs were assessed as greater than 5% dehydrated, exhibited epistaxis, were anorectic, anuric, or febrile for more than 24 hours, or had episodes of vomiting or diarrhea that did not resolve within 24 hours. Prior to necropsy,

dogs were injected with furosemide<sup>a</sup> to increase urine production to enhance the probability of being able to collect urine for leptospiral culture.<sup>13</sup> After euthanasia with an overdose of sodium pentobarbital,<sup>b</sup> liver, kidney, and urine samples were collected aseptically for culture and immunofluorescence testing. Samples of kidney, liver, lung, hepatic lymph node, adrenal gland, spleen, heart, tonsil, mesenteric lymph node, pancreas, stomach, jejunum, vulva, bladder, bone marrow, iliac lymph node, colon, ileum, and cecum were placed in 10% neutral buffered formalin, and samples of eye and conjunctiva were placed in Bouin's solution.

**Histopathology**—Formalin-fixed tissues for histologic evaluation were processed by standard paraffin embedding techniques after 24 hours. Sections were cut at 5  $\mu\text{m}$  except kidney, lymph nodes, and adrenal gland, which were cut at 3  $\mu\text{m}$ . All sections were stained with hematoxylin and eosin. Histopathologic grading of selected lesions of liver, kidney, and pancreas was done using no change (-), mild (+), moderate (++), and severe (+++) designations. For interstitial nephritis, tubular mineralization, and hepatic perivascular infiltrates the scores were assigned as follows: (-) = no change from control dogs, (+) = 1-3 foci/section examined, (++) = 4-6 foci/section examined, (+++) = (>6 foci/section examined). Tubular degeneration was graded (+) when scattered cells were noted with pyknotic nuclei or loss of polarity, (++) when these changes were present in larger sections of a tubule, and (+++) when multiple tubules in an area were affected. Tubular dilation was scored (+) when scattered tubular lumens were markedly widened and lined by a thin layer of epithelium, (++) when multiple tubules were affected, and (+++) when the cortex was diffusely affected. Hepatocyte individualization was scored (+) when hepatocyte cell margins were more distinct than controls, (++) when there were small clusters or groups of hepatocytes without

connections to adjacent cells, and (+++) when this change was present in large sheets of cells. Pancreatitis was (+) when small numbers of inflammatory cells were present between lobules, (++) when there was infiltration of the lobules by inflammatory cells, and (+++) for diffuse inflammation throughout the pancreas.

**Bacteriologic culture**—Blood cultures were performed on post-inoculation days 6, 8, 10, 12, 14, 22, and 28. Liver and kidney samples of approximately 1 gram and aqueous humor and urine samples of 1 ml were obtained at necropsy and processed for isolation of leptospire. Three media were used to increase the likelihood of isolating leptospire. First, Tween 80/Tween 40/lactalbumin hydrolysate was used as previously described<sup>14</sup> with slight modifications: 5-fluorouracil<sup>15</sup> was used at a rate of 100µg/ml and naladixic acid was not used. Second, Ellinghausen-McCullough-Johnson-Harris (EMJH) semisolid media was used as previously described<sup>16</sup> with 1% BSA, 100 µg/ml 5-fluorouracil<sup>c</sup> and 1% rabbit serum. Finally, commercial Polysorbate Leptospira Medium 5<sup>d</sup> was used with the addition of purified agar<sup>e</sup> and 100µg/ml 5-fluorouracil. Cultures were incubated at 29° C for 6 months. Darkfield exam was performed at 1, 2, 4, 6, and 8 weeks and at 3, 4, 5, and 6 months. If cultures became contaminated, approximately 1 ml was filtered through a 0.22 µm filter into new medium. Representative isolates were identified by restriction endonuclease analysis of chromosomal DNA.<sup>17</sup>

**Serologic examination**—Blood was obtained from dogs 6 days prior to inoculation and at days 7, 14, 22, and 28 post-inoculation. Prior to inoculation (Day 0), all dogs were free from agglutinating antibodies to serovar Grippotyphosa by the Microscopic Agglutination Test (MAT).<sup>9</sup> Blood was collected from seven strain 82 inoculated dogs, nine strain RM 52 inoculated dogs, and four control dogs at necropsy for serology.

**Immunofluorescence test**—Samples of urine, kidney, aqueous humor, and liver were stained with fluorescein-labeled rabbit anti-leptospiral conjugate as previously described.<sup>18</sup> Leptospire were identified by typical size, morphology, and fluorescence when examined by incident light fluorescence microscopy.

**Immunohistochemistry**—Immunohistochemical staining was done on a subset of animals to determine the patterns of antigen distribution after infection was confirmed by positive culture or immunofluorescence. A monoclonal mouse antibody with reactivity demonstrated specific to *Leptospira kirschneri* serovar Grippotyphosa was used as previously described with some modifications.<sup>10, 19</sup> Briefly, 5 µm sections were cut, placed on positively charged slides, and deparafinized with xylene and ethanol by standard procedures. Slide mounted tissue sections were rinsed in potassium phosphate buffered solution (KPBS; 0.15 M NaCl, 0.034 M K<sub>2</sub>HPO<sub>4</sub>, 0.017 M KH<sub>2</sub>PO<sub>4</sub>, pH 7.4), and antigen retrieval was performed by incubating slides for 7 minutes in 37 C KPBS with 0.1% trypsin and 0.1% CaCl<sub>2</sub>. After 2 rinses in KPBS, endogenous peroxidase activity was eliminated by a 30 minute incubation in 0.3% hydrogen peroxide solution in KPBS. The sections were then incubated for two hours in blocking solution (KPBS with 1% bovine serum albumin,<sup>f</sup> 0.4% Triton X-100<sup>g</sup>, and 1.5% normal blocking serum,<sup>h</sup> and incubated overnight at room temperature (24°C) in primary antiserum. On the following day, tissue sections were rinsed in KPBS with 0.2% Triton X-100 and incubated in an appropriate biotinylated secondary antibody for two hours at room temperature, rinsed, and incubated in Horseradish Peroxidase-Avidin-Biotin Complex<sup>i</sup> for 1 hour at room temperature. Enzyme reactions were developed with a substrate kit<sup>j</sup> producing a red reaction. The reaction was terminated in successive rinses of 0.9% NaCl solution.



Slides were counterstained with hematoxylin, dehydrated through graded alcohols, and coverslipped.

## RESULTS

**Clinical signs and microbiology**—A dog was considered infected if leptospire were detected in tissues or body fluids by culture, immunofluorescence, or immunohistochemistry (see Table 1). Culture and immunofluorescence test results were negative in all control dogs (5/5; 100%). Serovar Grippotyphosa was detected in 3 of 14 (21%) RM52 inoculated dogs and in all (12/12; 100%) strain 82 inoculated dogs (see Table I). No blood cultures were positive on day 5 PI, but all were positive on day 7 PI. The 3 dogs without positive urine culture or immunofluorescence test were necropsied on day 7 PI. Mild reddening of the

Table 1- Summarized results of bacterial culture and immunofluorescence (FA) testing expressed as number of positive results obtained/number of animals tested per group.

	Blood	Kidney	Liver	Urine	Aq. Humor	Kidney FA	Liver FA	UrineFA
Control	0/5	0/5	0/5	0/5	0/5	0/5	0/5	0/5
Strain 82	12/12	11/12	12/12	6/9*	9/12	10/12	8/12	5/9*
RM52	3/14	3/14	3/14	1/14	1/14	2/14	2/14	0/14

\*samples unavailable from 3 dogs

sclera and conjunctiva occurred in all leptospire-inoculated dogs on day 1 PI (the second inoculation day). On day 5 PI, inoculated dogs were lethargic, and one dog from each of serovar Grippotyphosa inoculated groups had more severe reddening of the sclera and conjunctivitis with thick ocular discharge. On day 8 PI, two dogs inoculated with strain 82 were febrile (40.1 C and 40 C, respectively). A third dog was febrile (39.4 C) on day 9 PI. Clinical signs that indicated euthanasia and necropsy should be performed prior to the scheduled date were lethargy, dehydration, depression, subnormal temperature,

conjunctivitis, and icterus. Necropsy was done prior to the scheduled date for a total of 11 dogs: on day 9 PI (n=1; strain 82 group), day 10 PI (n=2; strain 82 group), day 12 PI (n=2 strain RM52 group; n=5 strain 82 group), and day 13 PI (n=1; strain RM 52 group). Remaining strain RM 52 inoculated dogs were necropsied on post-inoculation days 14 (n=3), 22 (n=4), and 28 (n=5).

Clinical signs prior to necropsy were similar between strain RM 52 and strain 82 infected dogs, but a greater percentage of strain 82 dogs showed clinical signs. Clinical assessments of dogs revealed groups of inoculated dogs were affected by dehydration [strain RM52 ( 2/14), strain 82 (7/12)], icterus [strain RM52 ( 2/14), strain 82 (9/12)], lethargy [strain RM52 ( 2/14 ), strain 82 ( 6/12)], coughing [strain RM52( 1/14 ), strain 82 (1/12)], diarrhea [strain RM52 (3/14), strain 82 (6/12)], and vomiting [strain RM52 (2/14 ), strain 82 (5/12)].

**Necropsy**—Gross findings on external examination included icterus, conjunctivitis, and ocular discharge. At necropsy, lesions were found in the kidneys, liver, and lungs (Table 2). Lesions on post-mortem examination were similar for all dogs necropsied on days 9, 10, 11, and 12 and included icterus of the sclera, gingiva, and subcutaneous tissue; friable, pale liver with enhanced lobular pattern; subcutaneous and retroperitoneal edema; multifocal petechiae in the lungs; prominent reddened lymph nodes (hepatic and/or internal iliac); and enlarged kidneys with perirenal edema. Typically, stomach and intestinal contents were scant. One strain 82 inoculated dog that was vomiting had a 10 cm ileocecal intussusception with devitalized ileum.

**Histopathology and immunohistochemistry**—Lesions of liver, kidney, and pancreas are reported (see table 2). Lesions in the liver included mixed perivascular

Figure 1- Photomicrograph of a section of liver obtained from a *L. kirschneri* serovar Grippotyphosa strain 82 inoculated dog (Dog 6) at 7 days PI. The portal area is infiltrated by small numbers of lymphocytes, plasma cells, and fewer neutrophils that surround the hepatic vein, lymphatic, and bile duct. H&E stain. Bar = 40  $\mu\text{m}$ .

Figure 2- Photomicrograph of a section of liver obtained from a strain 82 inoculated dog (Dog 9) at 9 days PI. The hepatocytes are individualized and the cytoplasm contains multiple small, clear vacuoles (lipid). H&E stain. Bar = 40  $\mu\text{m}$ .

Figure 3- Photomicrograph of a section of liver from a strain 82 inoculated dog at 12 days PI. Mitoses are frequent in sections obtained from infected dogs. The hepatocytes also contain lipid vacuoles. H&E stain. Bar = 40  $\mu\text{m}$ .

Figure 4- Photomicrograph of a section of kidney from a strain 82 inoculated dog (Dog 6) at 7 days PI. There is slight expansion of the interstitium by infiltrates of lymphocytes, plasma cells, and fewer neutrophils. H&E stain. Bar = 40  $\mu\text{m}$ .

Figure 5- Photomicrograph of a section of kidney from a strain 82 inoculated dog (Dog 15) at 12 days PI. The interstitium is expanded by edema fluid, free erythrocytes, and inflammatory infiltrates. There are multifocal dilated proximal convoluted tubules with thin epithelium. H&E stain. Bar = 140  $\mu\text{m}$ .

Figure 6- A higher magnification of the kidney in figure 5. The interstitial infiltrate is composed primarily of plasma cells, and lymphocytes. H&E stain. Bar = 40  $\mu\text{m}$ .

Figure 7- Photomicrograph of a section of pancreas from a strain 82 inoculated dog (Dog 6) at 7 days PI. The interlobular interstitium is infiltrated by moderate numbers of a mixed population of lymphocytes, plasma cells, neutrophils, and macrophages. H&E stain. Bar = 40  $\mu\text{m}$ .

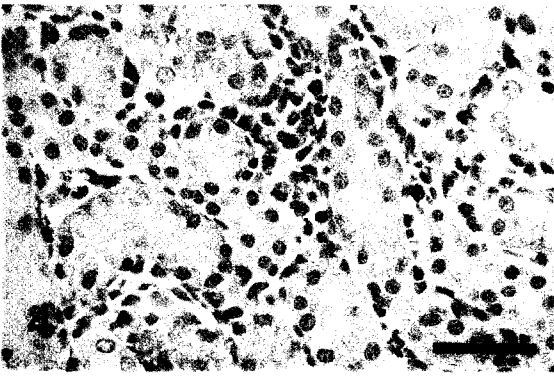
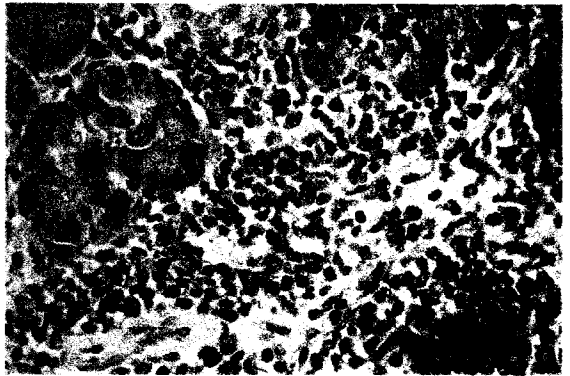

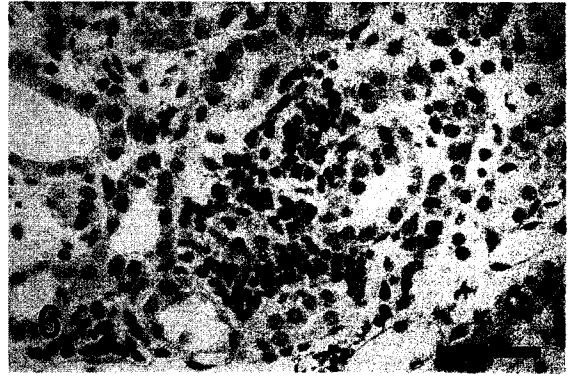
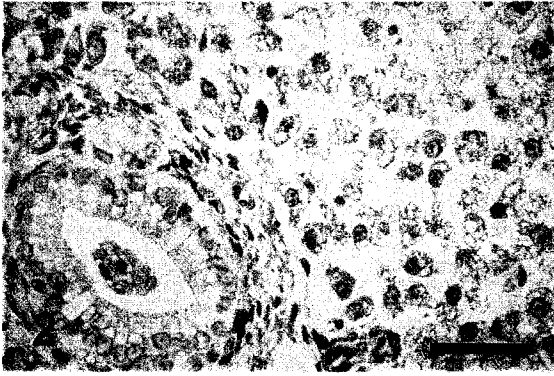
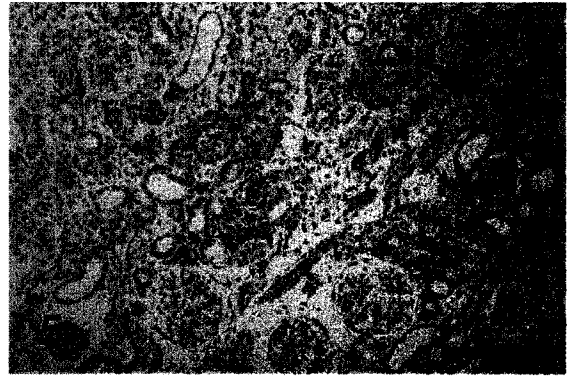
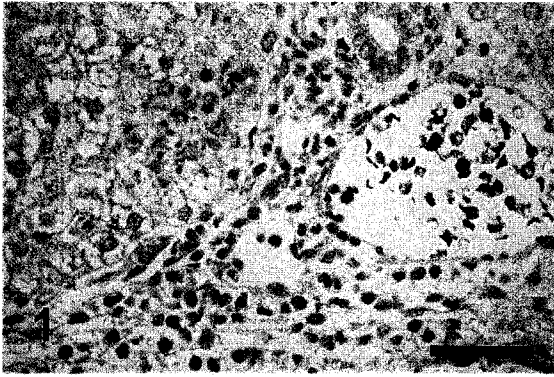


Table 2-The major lesions present in kidney, liver, and pancreas are summarized for each day post-inoculation (PI).

Group	Day PI	Kidney				Vasculitis	Liver		Pancreas
		Interstitial nephritis	Tubular Mineral	Tubular degeneration	Tubular dilation		Individualization	Necrosis	Interstitial pancreatitis
Controls	7	0/1	0/1	0/1	0/1	0/1	0/1	0/1	0/1
	14	0/1	0/1	0/1	0/1	0/1	0/1	0/1	0/1
	22	0/1	0/1	0/1	0/1	0/1	0/1	0/1	0/1
	28	0/2	0/2	0/2	0/2	0/2	0/2	0/2	0/2
Strain 82	7	3/3+	3/3-	1/3+ 2/3-	3/3-	1/3+++ 2/3+	3/3-	1/3+ 2/3-	1/3++ 1/3+ 1/3-
	9	1/1++	1/1-	1/1++	1/1-	1/1+	1/1+++	1/1+	1/1+
	10	1/1+++	1/1++	1/1+++	1/1-	1/1++	1/1++	1/1+	1/1+
	11	1/1+++	1/1-	1/1+++	1/1-	1/1+	1/1+	1/1+	1/1-
	#11	1/1+++	1/1+	ND	ND	1/1+	1/1++	1/1+	1/1+
	12	1/4+++	1/4++	2/4++	3/4++	1/4++	2/4+	3/4+	1/4+
		3/4++	1/4+	2/4+	1/4+	3/4+	2/4-	1/4-	2/4-
			2/4-						1/4 ND
	#12	1/1+++	1/1+++	1/1 ND	1/1 ND	1/1-	1/1++	1/1++	1/1-
	Strain RM52	7	3/3-	3/3-	3/3-	3/3-	3/3-	3/3-	3/3-
12		2/2+++	2/2-	1/2++ 1/2+	1/2++ 1/2+	1/2+++ 1/2++	1/2++ 1/2+	1/2++ 1/2-	2/2- 1/2-
13		1/1+++	1/1+	1/1+	1/1++	1/1-	1/1-	1/1+	1/1+
14		2/2-	2/2-	2/2-	2/2-	2/2-	2/2-	2/2-	2/2-
22		3/3-	1/3++ 1/3-	3/3-	3/3-	2/3+ 1/3-	3/3-	3/3-	3/3-
28		3/3-	3/3-	3/3-	3/3-	3/3-	3/3-	3/3-	3/3-

- = no change evident; + = mild; ++ = moderate; +++ = severe  
 ND = not examined; PI=post-inoculation; # these animals died (were not euthanized)

infiltrates of neutrophils, lymphocytes, and plasma cells at days 7-12 PI (Fig. 1) and individualization of hepatocytes and piecemeal hepatic necrosis with multifocal plugs of bile pigment within bile canaliculi at days 9-12 PI (Fig. 2). Increased numbers of mitoses were often noted when compared to control tissues (Fig. 3). Prominent lesions in the kidney were interstitial nephritis, mineralization, tubular dilation, and tubular degeneration (Fig. 4-6). Infiltrates of neutrophils between lobules of the pancreas were present in six dogs (Fig. 7). Immunoreactivity to serovar Grippotyphosa lipopolysaccharide was present in proximal convoluted tubular lumina and within interstitial vessels. The sites of immunoreactivity were small and multifocal with a granular to globular appearance.

**Clinical Pathology findings**—Consistent clinical pathology alterations at necropsy in strain 82 infected dogs were azotemia, hyperphosphatemia, increased anion gap, hyperbilirubinemia, and increased alkaline phosphatase (Table 3). When necropsy data for BUN, Creatinine, phosphorus, anion gap, TCO<sub>2</sub>, ALT, ALP, GGT, and total bilirubin were compared to baseline values by the paired T-test for strain 82 inoculated dogs, there was evidence for a significant difference at the  $p < 0.001$  level. CBC results associated with disease in strain 82 infected dogs included leukocytosis with mature neutrophilia ( $p < 0.003$ ). The two strain RM52 infected dogs, for which samples were available for analysis had similar complete blood count and serum biochemical abnormalities that included neutrophilia, marked hyperkalemia, relative hypercalcemia, hypoalbuminemia, hyperphosphatemia, elevated BUN and creatinine, markedly elevated ALP, hyperbilirubinemia, and elevated anion gap (data not shown).

**Serology**—Three strain 82 inoculated dogs had titers at necropsy: two at 1:25 and one at 1:50. Three strain RM52 inoculated dogs had 1:25 titers at day 14, but agglutination

Table 3-Clinical pathology data for strain 82 infected dogs is summarized. Baseline values are compared to necropsy results using the paired t-test. There is evidence for a significant difference between baseline and post-infection values at the  $p < 0.001$  for values that suggest renal (BUN, creatinine, phosphorus, anion gap,  $\text{TCO}_2$ ) and hepatic (ALT, ALP, GGT, total bilirubin) lesions. Elevations in baseline values for ALP and Phosphorus relative to the reference interval were considered normal for dogs of this age.

<u>Selected Parameters</u>	<u>Baseline</u>	<u>Reference Interval</u>	<u>Post-Infection</u>
BUN mg/dl*	15 ± 5	10 - 30	220 ± 52
Creatinine mg/dl*	0.3 ± 0.06	0.1 - 1.2	4.6 ± 1.5
Phosphorus mg/dl*	8.3 ± 0.7	3.2 - 6.2	21.9 ± 5.8
Anion Gap*	19.4 ± 1.5	11 - 20	37.1 ± 7.5
$\text{TCO}_2$ mEq/L*	23.9 ± 1.7	17 - 24	14.9 ± 2.8
ALT IU/L*	25.0 ± 4.4	24 - 105	71.4 ± 18.4
ALP IU/L*	173.0 ± 76.8	20 - 115	1269.1 ± 583.9
GGT IU/L*	5.8 ± 5.5	1 - 10	15.2 ± 3.7
Total Bilirubin mg/dl*	0.2 ± 0.1	0.1 - 0.6	4.8 ± 1.7
WBC $\times 10^6/\mu\text{l}$ *	15.6 ± 3.2	5.5 - 19.5	27.7 ± 5.9
Neutrophils $\times 10^6/\mu\text{l}$ †	10.8 ± 2.4	2.5 - 12.5	23.5 ± 5.1

\*Values mean ± SD. significantly different \* ( $p < 0.001$ ) or † ( $p < 0.003$ ) paired t test.

was not noted in samples taken from two of these dogs at later time points. No other agglutinating antibody titers of 1:25 or greater were noted in strain RM 52 inoculated dogs.

## DISCUSSION

In this study, two different isolates of *Leptospira kirschneri* serovar Grippotyphosa were used to inoculate young, seronegative dogs. One isolate (strain RM 52) was derived from swine tissues whereas the other (strain 82) was isolated from the urine of a dog with a clinical leptospirosis. Clinical signs, onset of disease, and gross and microscopic lesions were similar between dogs infected with the two different isolates of serovar Grippotyphosa, but fewer dogs were infected after inoculation with the swine derived isolate, strain RM 52, (3/14) than after inoculation with the canine-derived isolate, strain 82 (12/12). Hamster passage was used to restore virulence prior to inoculation of dogs, but adaptation of strain RM 52 to culture conditions after multiple passages may have resulted in the loss of factors related to virulence<sup>22</sup> in dogs. Alternatively, the swine derived strain may not be as virulent for dogs. Cultured leptospire have been shown to express different proteins than host-derived leptospire.<sup>10</sup> Change in the expression patterns of proteins associated with bacterial entry of strain RM 52 after repeated culture is one explanation for the fewer dogs infected after inoculation with this organism. Strain 82 organisms were passed in culture only once since isolation from the original dog in 1992, which may have allowed retention of the characteristics that allowed it to infect the original host.

Clinical signs of canine leptospirosis are often nonspecific and may include fever, myalgia, anorexia, vomiting, and diarrhea,<sup>23,24</sup> and signs may vary depending on the infecting serovar. At seven days post-inoculation, signs were mild and limited to lethargy and mild scleral hyperemia. Dogs that became infected developed severe clinical signs as early as 9



days PI with clinical illness worsening and resulting in death or euthanasia up to day 13 PI. Other signs in acutely ill dogs in the 9 to 13 day post-inoculation period included lethargy, vomiting, and anorexia. Fevers were only detected in three strain 82 inoculated dogs. A greater incidence was expected since fever is commonly listed as a clinical sign of leptospirosis. As body temperature data were only collected twice daily, it is possible that a transient febrile period was missed in some dogs.

A previous study established that acute renal failure can occur in dogs as a result of infection with serovar Grippotyphosa, but suggested hepatic disease was a minor component.<sup>5</sup> In our study, serum biochemical profiles and histologic lesions of acutely ill dogs were indicative of severe renal and hepatic disease. At 7 days PI, lesions were present in kidney and liver. There were small multifocal lymphoplasmacytic interstitial infiltrates in the kidney and perivascular infiltrates of lymphocytes, plasma cells, and fewer neutrophils in the liver. Histologic lesions in acutely ill dogs on days 9-13 PI were more severe, with renal lesions consisting of more extensive lymphoplasmacytic interstitial nephritis, tubular dilation with flattened epithelium (a sign of tubular repair after epithelial cell loss), and multifocal tubular mineralization. Immunoreactivity to serovar Grippotyphosa lipopolysaccharide was demonstrated in small quantities in renal tubular lumina and interstitial vessels. Staining was less intense than in dogs described previously.<sup>19</sup> The amount of immunoreactivity may be related to duration of infection, but the duration of infection in the previous study in which this antibody was applied to canine tissue was not known. In the liver, hepatocytes had lost glycogen stores, contained numerous small clear vacuoles (lipid), and were individualized and dissociated from hepatic laminae. Multifocal bile plugs were present, and lymphocytes and neutrophils were increased around hepatic portal veins and diffusely throughout the sinusoids.

One dog had an intussusception at necropsy, a finding that has been previously described in leptospirosis.<sup>20, 24, 25</sup> Elevated biochemical parameters in non-recovering dogs indicated renal and hepatic damage and acid-base abnormalities. There were significant elevations in BUN, creatinine, and phosphorus in blood drawn at the time of necropsy compared to baseline values indicating that greater than 75% of the renal parenchyma was affected. Elevated ALT indicates leakage of hepatocytes, and markedly elevated ALP, GGT, and bilirubin indicate cholestasis. Bile flow was most likely disrupted by the dissociation of hepatocytes from hepatic laminae and swelling of hepatocytes due to lipid accumulation. Elevated anion gap and decreased TCO<sub>2</sub> indicated metabolic acidosis, likely titrational with loss of bicarbonate due to overabundance of uremic acids. Two acutely ill strain RM 52 dogs were markedly hyperkalemic due to potassium redistribution and failure of renal potassium excretion (anuria/oliguria). Redistribution occurs in acidosis when H<sup>+</sup> moves intracellularly and K<sup>+</sup> becomes extracellular resulting in increased extracellular K<sup>+</sup> levels.<sup>26</sup>

Dogs inoculated with strain RM 52 and necropsied on days 14, 22, or 28 PI did not have lesions except for two dogs with mild perivascular hepatic infiltrates. These dogs did not have evidence of infection by culture, immunofluorescence, or serologic testing. It is possible that organisms never entered the vasculature at the mucous membrane surface, or organisms entered the bloodstream, but were cleared before attempts were made to culture the blood. Previous experiments show that leptospire can be rapidly phagocytosed by tissue macrophages after inoculation.<sup>27</sup> Since control dogs did not have lesions similar to the inoculated dogs, these mild lesions in kidney and liver may have been the result of tissue damage due to leptospire present transiently in those tissues prior to phagocytosis.

Serologic tests for leptospirosis in dogs include the MAT<sup>9</sup> and enzyme-linked immunosorbent assay.<sup>28</sup> The MAT is commonly used as a diagnostic test in clinical situations, so serum samples of all inoculated dogs were analyzed, if available. However, the results of serologic tests can be confounded by several factors. Serology is complicated by antibody cross-reactivity between different serovars and the presence of low-titers during acute disease.<sup>3, 5, 7</sup> Previously vaccinated dogs may have elevated titers that further complicate diagnosis, and some dogs may become infected and actively shed organisms without ever having a titer greater than 1:100<sup>29</sup> while others become seronegative after appropriate treatment.<sup>30</sup> No serologic titers greater than 1:50 were obtained from any dog inoculated with either strain of serovar Grippotyphosa in this experiment. The most likely explanation for this result is the short time period between inoculation and the onset of clinical illness.

To better understand the course of clinical disease and biochemical abnormalities in dogs infected with leptospirosis, 26 dogs were inoculated with *Leptospira kirschneri* serovar Grippotyphosa. To the authors' knowledge, this is the first complete, published study to report results of experimental mucous membrane inoculation with serovar Grippotyphosa. Two strains of serovar Grippotyphosa were used: strain RM 52 a swine derived isolate and strain 82 a canine isolate. Biochemical changes, gross and histopathologic lesions, and positive culture and immunofluorescence results occurred in a greater number of dogs inoculated with the canine isolate. However, the character of gross, histologic, and biochemical lesions were similar in time course and severity in dogs infected by either strain. Lesions and clinical pathology results suggest that infection with serovar Grippotyphosa results in severe renal and hepatic damage. The reason for the different rate of infection between these two different strains of serovar Grippotyphosa is not clear, but may be due to

changes that occurred in the original host (canine vs. swine), altered bacterial protein expression from culture passage, or differences in isolates from different geographical areas. Because of the efficient rate of infection and consistent production of hepatic and renal lesions strain 82 would make a good candidate for use in further study of treatment and preventative measures for acute canine leptospirosis.

<sup>a</sup> Lasix, Patheon Pharmaceuticals Inc., Cincinnati, OH 45215 USA

<sup>b</sup> Beuthanasia<sup>®</sup>-D Special, Schering-Plough Animal Health, Inc., Kenilworth, NJ 07033

<sup>c</sup> Sigma-Aldrich Corp., St. Louis, MO

<sup>d</sup> PLM 5, Intergen Co., Purchase, NY

<sup>e</sup> Becton, Dickinson and Company, Franklin Lakes, NJ

<sup>f</sup> BSA; Sigma, St. Louis, MO

<sup>g</sup> Fisher Chemicals, Fairlawn, NJ 07410

<sup>h</sup> NBS, donkey; Vector Laboratories Inc., Burlingame, CA 94010

<sup>i</sup> Vector Elite ABC Kit; 1:600; Vector, Burlingame, CA 94010

<sup>j</sup> NOVA RED, Vector Laboratories, Burlingame, CA 94010

## REFERENCES

1. Bolin CA. Diagnosis of leptospirosis: A reemerging disease of companion animals. *Semin Vet Med Surg (Small Anim)* 1996; 11: 166-171.
2. Ward MP, Glickman LT, Guptill LF. Prevalence of and risk factors for leptospirosis among dogs in the United States and Canada: 677 cases (1970-1998). *J Am Vet Med Assoc* 2002; 220: 53-58.
3. Adin CA, Cowgill LD. Treatment and outcome of dogs with leptospirosis: 36 cases (1990-1998). *J Am Vet Med Assoc* 2000; 216: 371-375.
4. Kalin M, Devaux C, DiFruscia R, et al. Three cases of canine leptospirosis in Quebec. *Can Vet J* 1999; 40: 187-191.
5. Brown CA, Roberts AW, Miller MA, et al. *Leptospira interrogans* serovar Grippotyphosa infection in dogs. *J Am Vet Med Assoc* 1996; 209: 1265-1267.

6. Menges RW, Galton MM, Habermann RT. Culture and serologic studies on four dogs inoculated with two leptospiral serotypes, *Leptospira pomona* and *Leptospira canicola*. *Am J Vet Res* 1960; 21: 371-376.
7. Rentko VT, Clark N, Ross LA, et al. Canine leptospirosis. A retrospective study of 17 cases. *J Vet Intern Med* 1992; 6: 235-244.
8. Birnbaum N, Barr SC, Center SA, et al. Naturally acquired leptospirosis in 36 dogs: Serological and clinicopathological features. *J Small Anim Pract* 1998; 39: 231-236.
9. Cole JR, Sulzer CR, Pursell AR. Improved microtechnique for the leptospiral microscopic agglutination test. *Appl Microbiol* 1973; 25: 976-980.
10. Barnett JK, Barnett D, Bolin CA, et al. Expression and distribution of leptospiral outer membrane components during renal infection of hamsters. *Infect Immun* 1999; 67: 853-861.
11. Thiermann A, McClellan R, Hill H. Improved techniques for the isolation of leptospire from swine abortion cases, in *Proceedings. 27th Annual Proceedings, Amer. Assn. Veterinary Laboratory Diagnosticians* 1984; 233-244.
12. Faine SA, B. Bolin, C. Perolat, P. In: *Leptospira and leptospirosis*. Melbourne: MediSci, 1999; 272.
13. Nervig RM, Garrett LA. Use of furosemide to obtain bovine urine samples for leptospiral isolation. *Am J Vet Res* 1979; 40: 1197-1200.
14. Ellis WA, Montgomery J, Cassells JA. Dihydrostreptomycin treatment of bovine carriers of *Leptospira interrogans* serovar Hardjo. *Res Vet Sci* 1985; 39: 292-295.
15. Johnson R, Rogers P. 5-fluorouracil as a selective agent for growth of *Leptospira*. *J Bact* 1963; 87: 422-426.
16. Johnson RC, Harris VG. Differentiation of pathogenic and saprophytic leptospire. I. Growth at low temperatures. *J Bacteriol* 1967; 94: 27-31.
17. Thiermann AB, Handsaker AL, Foley JW, et al. Reclassification of North American leptospiral isolates belonging to serogroups mini and sejroe by restriction endonuclease analysis. *Am J Vet Res* 1986; 47: 61-66.
18. Bolin CA, Thiermann AB, Handsaker AL, et al. Effect of vaccination with a pentavalent leptospiral vaccine on *Leptospira interrogans* serovar Hardjo type hardjo-bovis infection of pregnant cattle. *Am J Vet Res* 1989; 50: 161-165.
19. Wild CJ, Greenlee JJ, Bolin CA, et al. An improved immunohistochemical diagnostic technique for canine leptospirosis using anti-leptospiral antibodies on renal tissue. *J Vet Diagn Invest* 2002; 14: 20-24.
20. Keenan KP, Alexander AD, Montgomery CA. Pathogenesis of experimental *Leptospira interrogans*, serovar Bataviae, infection in the dog: Microbiological, clinical, hematologic, and biochemical studies. *Am J Vet Res* 1978; 39: 449-454.
21. Brenner DJ, Kaufmann AF, Sulzer KR, et al. Further determination of DNA relatedness between serogroups and serovars in the family *Leptospiraceae* with a proposal for *Leptospira alexanderi* sp. Nov. And four new *Leptospira* genomospecies. *Int J Syst Bacteriol* 1999; 49 Pt 2: 839-858.
22. Baranton G, Old I. The Spirochaetes: A different way of life. *Bull Inst Pasteur* 1995; 93: 63-95.

23. Taylor PL, Hanson LE, Simon J. Serologic, pathologic, and immunologic features of experimentally induced leptospiral nephritis in dogs. *Am J Vet Res* 1970; 31: 1033-1049.
24. Low DG, Hiatt CW, Gleiser CA, et al. Experimental canine leptospirosis. I. *Leptospira icterohemorrhagiae* infections in immature dogs. *J Infect Dis* 1956; 98: 249-259.
25. Hartman EG, van den Ingh TS, Rothuizen J. Clinical, pathological and serological features of spontaneous canine leptospirosis. An evaluation of the IgM- and IgG-specific ELISA. *Vet Immunol Immunopathol* 1986; 13: 261-271.
26. Brobst D. Review of the pathophysiology of alterations in potassium homeostasis. *J Am Vet Med Assoc* 1986; 188: 1019-1025.
27. Faine S. Reticuloendothelial phagocytosis of virulent leptospire. *Am J Vet Res* 1964; 25: 830-835.
28. Ribotta MJ, Higgins R, Gottschalk M, et al. Development of an indirect enzyme-linked immunosorbent assay for the detection of leptospiral antibodies in dogs. *Can J Vet Res* 2000; 64: 32-37.
29. van den Broek AHM, Thrusfield MV, Dobie GR, et al. A serological and bacteriological survey of leptospiral infection in dogs in Edinburgh and Glasgow. *J Small An Pract* 1991; 32: 118-124.
30. Harkin KR, Gartrell CL. Canine leptospirosis in New Jersey and Michigan: 17 cases (1990-1995). *J Am Anim Hosp Assoc* 1996; 32: 495-501.

#### **ACKNOWLEDGEMENTS**

The authors thank Rick Hornsby and the National Animal Disease Center Leptospirosis Group for sharing their expertise in techniques for leptospiral culture and detection and Stacy Friesen for her technical assistance in immunohistochemical staining.

**CHAPTER 3. EXPERIMENTAL CANINE LEPTOSPIROSIS CAUSED  
BY *LEPTOSPIRA INTERROGANS* SEROVARS POMONA AND  
BRATISLAVA**

A manuscript prepared for submission to *The American Journal of Veterinary Research*

Justin J. Greenlee, DVM; David P. Alt, DVM, PhD; Carole A. Bolin, DVM, PhD; Richard L.  
Zuerner, PhD; and Claire B. Andreasen, DVM, PhD, DACVP

From the Department of Veterinary Pathology, College of Veterinary Medicine, Iowa State University, Ames, IA (Greenlee, Andreasen), and the Bacterial Diseases of Livestock Research Unit, National Animal Disease Center, Agricultural Research Service, USDA, Ames, IA (Alt, Bolin, Zuerner)

\*Dr. Bolin's current address is Diagnostic Center for Population and Animal Health, College of Veterinary Medicine, Michigan State University, East Lansing, MI 48824

**ABSTRACT**

**Objective**— To determine the pattern of gross and histopathologic lesions and biochemical alterations caused by *Leptospira interrogans* serovars Pomona and Bratislava.

**Animals**—27 eight-week-old, female beagle dogs.

**Procedure**—Beagles were randomly assigned to challenge or control groups. Challenge groups were inoculated on three successive days by conjunctival instillation of  $5 \times 10^7$  cells of either *L. interrogans* serovar Pomona (n=12) or serovar Bratislava (n=11); control dogs (n=4) were inoculated with sterile leptospiral culture media. Clinical signs were recorded and

clinical pathology assays and necropsies (7/timepoint) were done at 7, 10, 14, and 20 days post-inoculation (PI).

**Results**— Infection could not be confirmed in any serovar Bratislava inoculated dog, and control dogs remained healthy throughout the experiment. Positive culture and fluorescent antibody test results were confirmed in 92% (11/12) of serovar Pomona inoculated dogs.

Fever and lethargy starting at day 7 PI were the most common clinical signs in serovar Pomona infected dogs. On day 10, gross lesions included multifocal renal and pulmonary hemorrhage and perirenal edema. Serovar Pomona inoculated dogs had histologic lesions including portal hepatitis, interstitial nephritis, and pneumonia at 7, 10, 14, and 20 days PI. Elevations in BUN, anion gap, and bilirubin occurred on days 10, 14, and 20 PI. Platelet counts from culture positive dogs were decreased from baseline values on days 10, 12, and 14 PI.

**Conclusions and Clinical Relevance**—Conjunctival inoculation with *L. interrogans* serovar Pomona, but not serovar Bratislava resulted in a high rate of infection with concomitant hemorrhagic and inflammatory lesions of the kidneys, liver, and lungs.

## INTRODUCTION

Leptospirosis, one of the most widespread zoonotic diseases,<sup>1</sup> is a reemerging cause of renal failure and hepatic disease in dogs.<sup>2</sup> The diagnosis of canine leptospirosis in the United States and Canada significantly increased between 1983 and 1998.<sup>3</sup> Traditionally, *Leptospira interrogans* serovars Canicola and Icterohemorrhagiae have been a major cause of canine leptospirosis. Experimental disease caused by serovars Canicola and Icterohemorrhagiae has been described,<sup>4-11</sup> and the use of vaccines containing these serovars has markedly reduced the incidence of disease caused by them.<sup>12, 13</sup> However, in the last



decade, other serovars such as *L. kirschneri* serovar Grippotyphosa and *L. interrogans* serovars Pomona and Bratislava have been associated with an increasing percentage of reported cases,<sup>2, 3, 12, 14-16</sup> and until recently, vaccines have not been available to protect against them. Features of canine leptospirosis that may be serovar specific have not been well characterized because of the paucity of experimental studies and the inability to determine the time of exposure in clinical cases. Experimental studies are needed to better understand the progression of clinical signs and clinicopathologic abnormalities in the course of disease with these re-emerging serovars. The purpose of this experiment was to inoculate dogs with *L. interrogans* serovars Pomona and Bratislava and document clinical signs, changes in CBC and biochemistry profiles, and gross and histologic lesions at necropsy.

## **MATERIALS AND METHODS**

**Dogs**—Twenty-seven 8-week-old female beagle dogs without detectable antibodies to *L. interrogans* serovars Bratislava or Pomona by Microscopic Agglutination Test (MAT)<sup>17</sup> were obtained from a commercial laboratory animal vendor.<sup>a</sup> Upon arrival dogs were examined for uniformity and randomly divided into three groups: 4 control dogs, 12 serovar Pomona inoculated dogs, and 11 serovar Bratislava inoculated dogs. Inoculated dogs were housed in BL-2 rooms at Iowa State University. Dogs were housed in pairs in a room maintained at a constant temperature and humidity. Cages were cleaned once daily and food and water were available at all times and freshened twice daily. All animal experiments were performed with the approval of the Iowa State University Committee on Animal Care.

**Leptospira preparation**— Two different bacterial isolates were used. *L. interrogans* serovar Pomona type kennewicki strain RM211 was isolated at the USDA/ARS-National Animal Disease Center from neonatal kidney and liver tissues from an Iowa swine herd that

were submitted to the Veterinary Diagnostic Laboratory at Iowa State University.<sup>18</sup> The herd had a history of 25 of 75 pregnancies resulting in abortion or stillbirth. *L. interrogans* serovar Bratislava strain Alex was isolated from urine obtained from a dog in Indiana with a 1:640 titer to serovar Bratislava by microscopic agglutination test (MAT).<sup>19</sup>

**Experimental design**— Inoculations occurred after a 6 day acclimation period. Two days prior to inoculation, samples were taken from each dog for complete blood count, serum biochemistry profile, and urinalysis, and no abnormalities were noted. The dogs were observed for clinical signs at least twice daily and temperatures recorded once daily throughout the experiment. Dogs were challenged on three consecutive days (Day 0, 1, and 2) with  $5 \times 10^7$  leptospire in 250  $\mu$ l of 80/40 liquid culture media<sup>20</sup> per eye ( a concentration of  $2 \times 10^8$  per ml), which was placed onto the corneal surface of each eye of each dog and allowed to run onto the conjunctiva. Dogs 1-4 (N=4) served as controls and were inoculated with an equal volume of sterile culture media. Dogs 5-16 (N=12) were inoculated with *L. interrogans* serovar Pomona type kennewicki strain RM 211. Dogs 17-27 (N=12) were inoculated with *L. interrogans* serovar Bratislava strain Alex.

**Necropsy and Sample collection**—On days 5, 8, and 12 of the experiment and at necropsy, blood was drawn for blood culture. Prior to necropsies done on days 7, 10, 14, and 20 additional blood samples were drawn from all dogs for CBC and serum biochemistry panels including sodium, potassium, chloride, total CO<sub>2</sub> (TCO<sub>2</sub>), calcium, phosphorus, blood urea nitrogen, creatinine, glucose, total protein, albumin, alanine aminotransferase (ALT), alkaline phosphatase (ALP),  $\gamma$ -glutamyltransferase (GGT), creatine kinase (CK), direct bilirubin (Dbili), total bilirubin (Tbili), and anion gap. For each time point, 3 dogs inoculated with each serovar and one control dog were necropsied. During necropsy, liver,

kidney, and urine were taken aseptically for culture and immunofluorescence testing. Samples of kidney, liver, lung, hepatic lymph node, adrenal gland, spleen, heart, tonsil, mesenteric lymph node, pancreas, stomach, jejunum, vulva, bladder, bone marrow, iliac lymph node, colon, ileum, and cecum were collected into 10% neutral buffered formalin. An eye and conjunctival sample were collected into Bouin's solution.

**Histopathology**—Tissues for histologic evaluation were collected into 10% neutral buffered formalin and processed by standard paraffin embedding techniques after 24 hours. Sections were cut at 5  $\mu\text{m}$  except for kidney, lymph nodes, and adrenal gland, which were cut at 3  $\mu\text{m}$ . All sections were stained with hematoxylin and eosin. Histopathologic grading of selected lesions of liver, kidney, and pancreas was done using no change (-), mild (+), moderate (++) , and severe (+++) designations. For interstitial nephritis, tubular mineralization, and hepatic vasculitis the scores were assigned as follows: (-) = no change from control dogs, (+) =1-3 foci/section examined, (++) =4-6 foci/section examined, (+++) = (>6 foci/section examined). Tubular degeneration was graded (+) when scattered cells were noted with pyknotic nuclei or loss of polarity, (++) when these changes were present in larger sections of a tubule, and (+++) when multiple tubules in an area were affected. Tubular dilation was scored (+) when scattered tubular lumens were markedly widened and lined by a thin layer of epithelium, (++) when multiple tubules were affected, and (+++) when the cortex was diffusely affected. Pancreatitis was (+) when small numbers of inflammatory cells were present between lobules, (++) when there was infiltration of the lobules by inflammatory cells, and (+++) for diffuse inflammation throughout the pancreas.

**Bacteriologic culturing and Polymerase Chain Reaction**—Blood cultures were performed on post-inoculation days 5, 8, 10, 12, 14, and 20. Liver and kidney samples of

approximately 1 gram and aqueous humor and urine samples of 1 ml were obtained at necropsy and processed for isolation of leptospire. Three media were used for isolations. First, Tween 80/Tween 40/lactalbumin hydrolysate was used as previously described<sup>20</sup> with slight modifications: 5-fluorouracil was used at a rate of 100µg/ml, and naladixic acid was not used. Second, Ellinghausen-McCullough-Johnson-Harris (EMJH) semisolid media was used as previously described<sup>21</sup> with the modifications of 10% BSA, 100 µg/ml 5-fluorouracil, and 1% rabbit serum. Finally, commercial Polysorbate Leptospira Medium 5<sup>b</sup> was used with the addition of purified agar and 100µg/ml 5-fluorouracil. Cultures were incubated at 29° C for 6 months. Darkfield exam was performed at 1, 2, 4, 6, and 8 weeks and at 3, 4, 5, and 6 months. If cultures became contaminated, approximately 1 ml was filtered through a 0.22 µm filter into new medium. Representative isolates were identified by restriction endonuclease analysis of chromosomal DNA.<sup>22</sup> Isolation of genomic DNA was done using a commercial kit<sup>c</sup> and amplification by PCR was performed on kidney as previously described.<sup>23</sup>

**Serologic examination**—Blood was obtained from dogs prior to inoculation and at days 7, 10, 14, and 20 post-inoculation. Serum was separated and tested for the presence of agglutinating antibodies against serovars Pomona or serovar Bratislava, respectively, using the microscopic agglutination test.<sup>17</sup>

**Immunofluorescence test**—Samples of urine, kidney, aqueous humor, and liver were stained with equal amounts of fluorescein-labeled rabbit anti-serovar conjugate as previously described.<sup>24</sup> Leptospire were identified by typical size, morphology, and fluorescence when examined by incident light fluorescence microscopy.

**Immunohistochemistry**— Immunohistochemical staining was done on a subset of animals to determine the patterns of antigen distribution after infection was confirmed by positive culture or immunofluorescence. Two primary antisera were used at the stated dilutions: polyclonal rabbit antisera specific to the outer membrane protein OmpL1,<sup>25</sup> #338 (1:6,000); and polyclonal rabbit antisera with serovar Pomona specificity (1:8,000) as previously described.<sup>26</sup> Briefly, 5  $\mu$ m sections were cut, placed on positively charged slides, and deparafinized with xylene and ethanol by standard procedures. Slide mounted tissue sections were rinsed in potassium phosphate buffered solution (KPBS; 0.15 M NaCl, 0.034 M K<sub>2</sub>HPO<sub>4</sub>, 0.017 M KH<sub>2</sub>PO<sub>4</sub>, pH 7.4), and antigen retrieval was performed by incubating slides for 7 minutes in 37 C KPBS with 0.1% trypsin and 0.1% CaCl<sub>2</sub>. After 2 rinses in KPBS, endogenous peroxidase activity was eliminated by 30 minute incubation in 0.3% hydrogen peroxide solution in KPBS. The sections were then incubated for two hours in blocking solution (KPBS with 1% bovine serum albumin,<sup>d</sup> 0.4% Triton X-100,<sup>e</sup> and 1.5% normal blocking serum,<sup>f</sup> and incubated overnight at room temperature (24°C) in primary antiserum. On the following day, tissue sections were rinsed in KPBS with 0.2% Triton X-100 and incubated in an appropriate biotinylated secondary antibody for two hours at room temperature, rinsed, and incubated in Horseradish Peroxidase-Avidin-Biotin Complex<sup>g</sup> for 1 hour at room temperature. Enzyme reactions were developed with a substrate kit producing a red reaction.<sup>h</sup> The reaction was terminated in successive rinses of 0.9% NaCl solution. Slides were counterstained with hematoxylin, dehydrated through graded alcohols, and coverslipped.

## RESULTS

**Clinical signs and microbiology**— Clinical signs in serovar Pomona inoculated dogs began 7 days PI and included lethargy, fever, and inappetence. Seven serovar Pomona inoculated dogs were febrile (range 39.3 C to 40.2) on days 7 (1/7), 8-9 (2/7), 11-13 (3/7), and 17-18 (1/7). Three serovar Pomona inoculated dogs had loose feces with small amounts of blood on days 7 to 10 PI. One dog necropsied on day 20 presented with a wasting syndrome characterized by poor food intake, rough hair coat, scant, dark feces, and weight loss. Clinical signs were not detected in control or serovar Bratislava inoculated dogs.

A dog was considered infected if leptospire were detected in tissues or body fluids by culture, immunofluorescence, or immunohistochemistry. Culture and immunofluorescence test results (Table 1) were negative in all control dogs (5/5; 100%). Serovar Bratislava was not detected in any tissue by bacterial culture or immunofluorescence testing. Serovar Pomona was detected 11 of 12 (92%) inoculated dogs. Blood culture of Pomona inoculated dogs (11/12) was positive at 7 or 8 days PI, but infection could not be confirmed by any other method at those early times. Culture, immunofluorescence testing, and PCR methods were positive in these dogs (8/9) after day 10 PI. Leptospire were cultured from kidney (8/9), urine (5/7), aqueous humor (5/9), and liver (6/9) at day 10 PI or later, and 11 of 12 dogs were positive by PCR during that time period. Immunofluorescence testing demonstrated leptospiral antigen in kidney (8/9), liver (6/9), and urine (5/7) at necropsy when performed at day 10 PI or later.

**Necropsy**—No abnormalities, except ocular discharge and conjunctival hyperemia in 2 serovar Pomona inoculated dogs at day 10 PI were noted upon external examination prior to necropsy. One serovar Pomona inoculated dog necropsied at day 10 PI continued to bleed

Table 1- Summarized results of bacterial culture and immunofluorescence (FA) testing expressed as number of positive results obtained/number of animals tested per group.

	<u>Culture</u>								<u>Immunofluorescence Test</u>		
	Blood 5 PID	Blood 8 PID	Blood 12 PID	Blood*	Kidney	Liver	Urine	Aq. Humor	Kidney	Liver	Urine
Control	0/4	0/4	0/4	0/4	0/4	0/4	0/4	0/4	0/4	0/4	ND
serovar Pomona	0/12	8/9	5/6	6/8	8/12	6/12	5/10	5/12	8/12	6/12	5/7
serovar Bratislava	0/11	0/9	0/6	0/11	0/11	0/11	0/11	0/11	0/11	0/11	0/10

\*necropsy sample

for an abnormally long period of time after venipuncture. Gross lesions were evident in serovar Pomona inoculated dogs necropsied on days 10, 14, and 20 and consisted of multifocal pulmonary (Fig. 1) and renal hemorrhage (Fig. 2-3), perirenal edema, friable liver with multifocal 1-2 mm raised white foci, and enlarged and reddened hepatic and internal iliac lymph nodes. One serovar Pomona inoculated dog (see wasting syndrome above), which had been febrile on days 11 and 13 and necropsied at day 20 had dark, bloody feces; a friable, pale, and yellow liver; and multiple brown ecchymotic pulmonary hemorrhages. No gross lesions were present in serovar Bratislava inoculated dogs.

**Histopathology and Immunohistochemistry**—Tissues from 7, 10, 14, and 20 day necropsies of serovar Pomona inoculated dogs had histologic lesions in liver, kidney, and lungs. Lesions at day 7 were subtle and confined to perivascular inflammation in the liver and multifocal interstitial nephritis. A single serovar Pomona dog had a focus of coagulative hepatic necrosis. On day 10, there was pulmonary (Fig. 4) and renal hemorrhage (Fig. 5), coalescing interstitial nephritis, and heavier infiltrates of lymphocytes, plasma cells, and neutrophils in portal areas and around hepatic portal veins. On day 14 and 20, multifocal renal hemorrhage was present, interstitial nephritis was more intense (Fig. 6), and hyaline droplets (Fig. 7) were prominent in the tubular epithelium. Periportal inflammatory infiltrates of lymphocytes, plasma cells, neutrophils, and macrophages were denser, there were a few small foci of hepatic necrosis, and multifocal bile plugs within bile canaliculi. Dilated proximal convoluted tubules with flattened epithelium and mineral deposits were present at day 20 PI only. Lesions that occurred less frequently in infected dogs were renal tubular syncytia, endocarditis and epicarditis, and focal pneumonia. In the heart, there were infiltrates of neutrophils, lymphocytes, and fewer plasma cells around multiple veins and

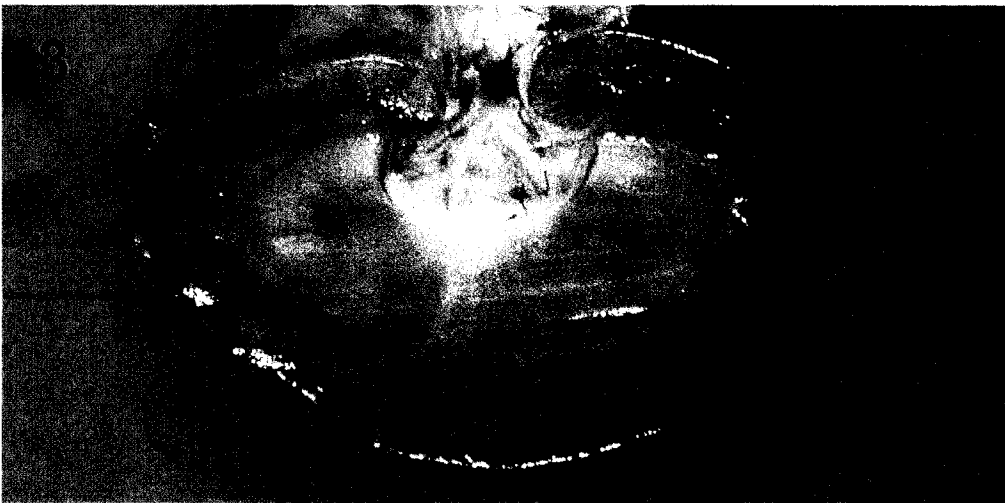
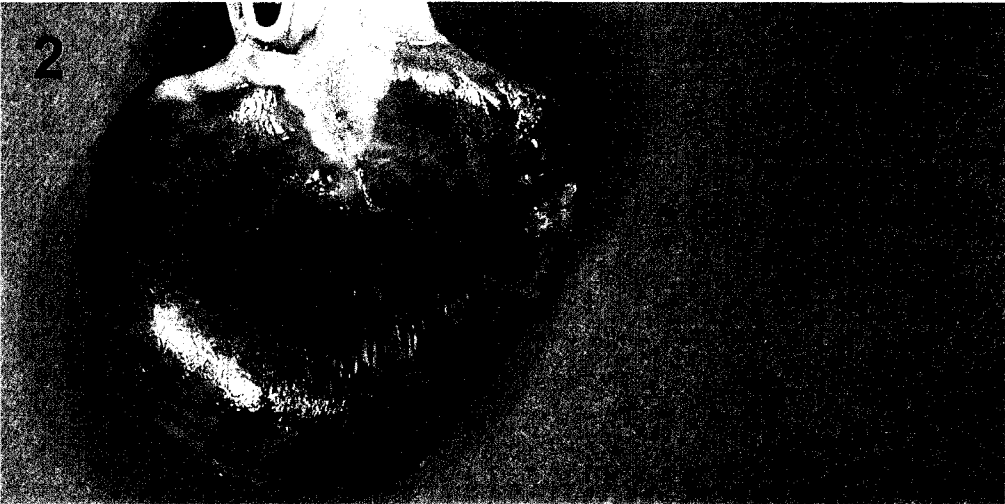
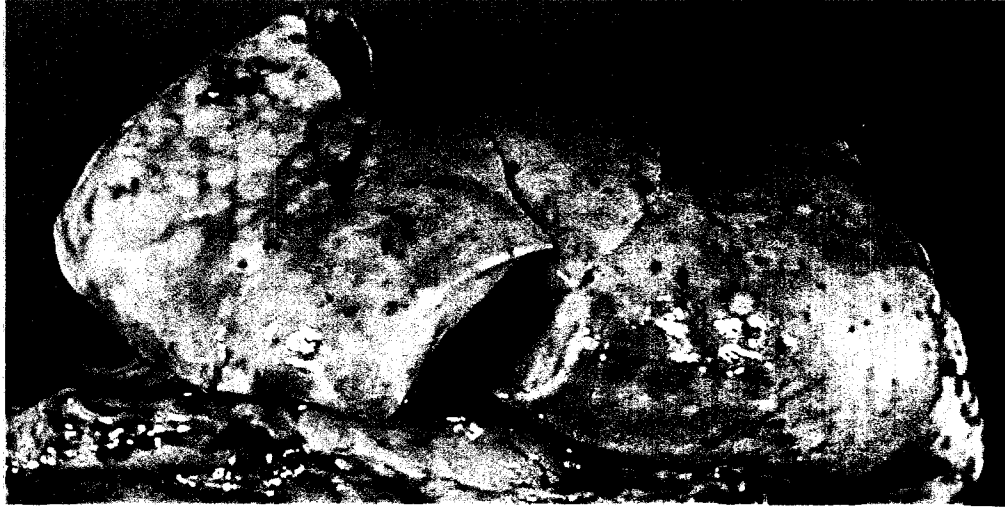## FIGURE LEGENDS

Figure 1- Right lung from a *Leptospira interrogans* serovar Pomona strain RM 211 inoculated dog at 10 days PI. There are multifocal petechial hemorrhages that occasionally coalesce.

Figure 2- Kidney from a serovar Pomona inoculated dog at 10 days PI. There are multifocal subcapsular hemorrhages.

Figure 3- Kidney from a serovar Pomona inoculated dog at 10 days PI. Multifocal irregularly shaped hemorrhages extend from the cortical surface to the cortico-medullary junction.



## FIGURE LEGENDS

Figure 4- Photomicrograph of a section of lung from a serovar Pomona inoculated dog at 10 days PI. Multiple alveoli are filled with free erythrocytes. H&E stain. Bar=50  $\mu\text{m}$ .

Figure 5- Photomicrograph of a section of kidney from a serovar Pomona inoculated dog at 10 days PI. The interstitium is expanded by edema fluid, free erythrocytes, and infiltrates of lymphocytes, plasma cells, and neutrophils. H&E stain. Bar=50  $\mu\text{m}$ .

Figure 6- Photomicrograph of a section of kidney from a serovar Pomona inoculated dog at 20 days PI. Interstitial infiltrates are composed primarily of plasma cells, and lymphocytes. H&E stain. Bar=50  $\mu\text{m}$ .

Figure 7- Photomicrograph of a section of kidney from a serovar Pomona inoculated dog at 20 days PI. Hyaline droplets are abundant in proximal convoluted tubular epithelial cells. H&E stain. Bar=20  $\mu\text{m}$ .

Figure 8- Immunohistochemical staining of a section of kidney from a serovar Pomona inoculated dog at 20 days PI. There is immunoreactivity with polyclonal 338 (antisera to OmpL1) within multifocal proximal tubules, but not within foci of interstitial inflammation. Bar=50  $\mu\text{m}$

Figure 9- A higher magnification of the immunohistochemical staining in figure 8. Intense immunoreactivity to leptospiral antigens is associated with organisms attached to the microvillous surface of the proximal convoluted tubule. Bar=20  $\mu\text{m}$

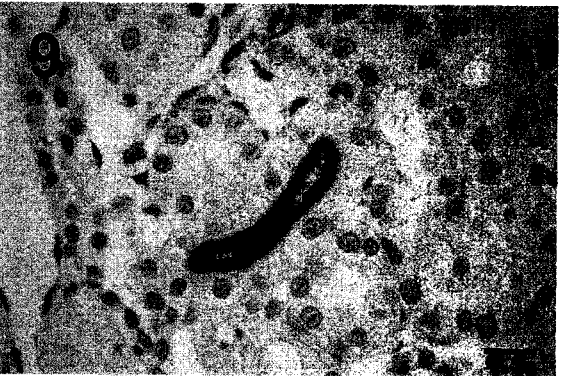

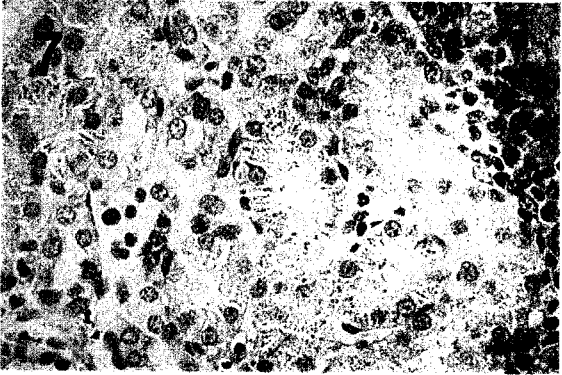
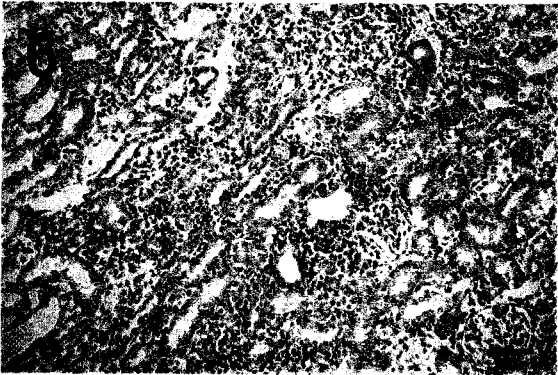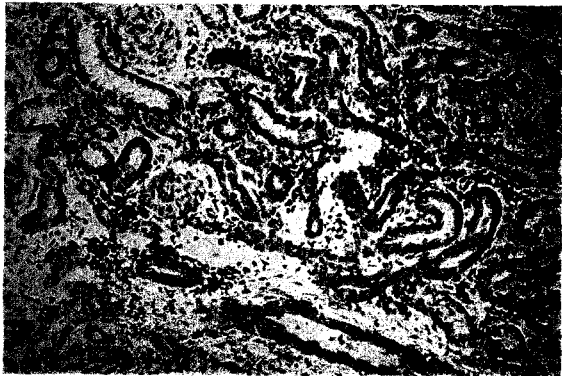



Table 2- The major histologic lesions present in kidney and liver are summarized for each day post inoculation (PI).

Group	Kidney			Liver	
	Interstitial nephritis	Tubular Mineral	Tubular degeneration and dilation	Hepatitis	Bile plugs
Serovar Pomona					
	<u>Day PI</u>				
	7	3/3 +	2/3 +	1/3+	3/3 -
				1/3++	
	10	1/3 +			
		2/3 +++	2/3 +	2/3+	3/3-
				1/3+++	
	14	3/3 +++	1/3+	1/3+	1/3
			1/3++	1/3 +	1/3 ++
	20	1/3++	2/3+	1/3 +	1/3 +++
			1/3 +++		

lack of lesions (-) not listed unless all animals were negative

arteries, subjacent the endocardium, and within the epicardium and epicardial fat. In the lungs, groups of alveoli were filled and alveolar septa expanded with erythrocytes, serum, fibrin, degenerate neutrophils, and fewer lymphocytes and macrophages. In sections of perirenal fat examined from dogs with perirenal edema, there was necrosis of fat and heavy infiltrates of lymphocytes, plasma cells, neutrophils, and macrophages. Sections examined from the enlarged, reddened lymph nodes contained large numbers of free erythrocytes within the medulla. Erythrocytes often formed rosettes around or were within macrophages.

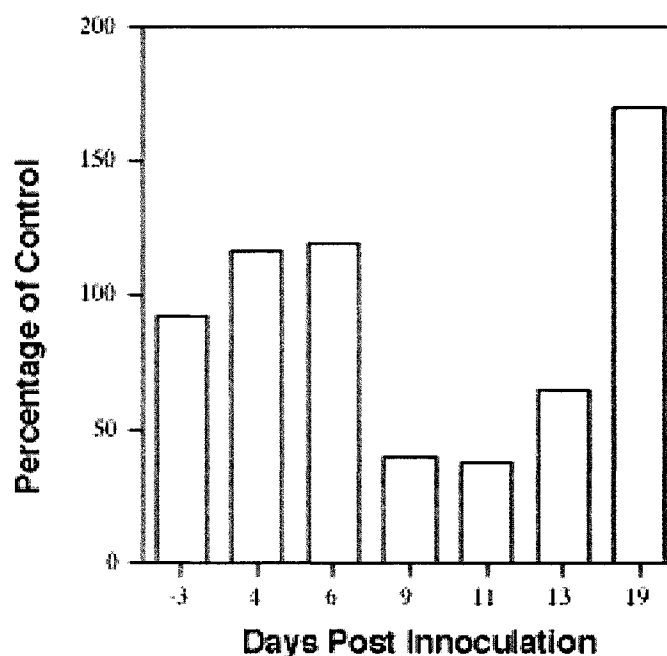
There was immunoreactivity to polyclonal antisera 338 at the brush border of multifocal proximal convoluted tubules (Fig. 8) and at the luminal surface of bile duct epithelium. The pattern of immunoreactivity was consistent with intact leptospire (Fig. 9). There was a similar pattern of immunoreactivity with the anti-pomona antisera. No intense immunoreactivity was noted in inflammatory infiltrates of kidney, liver, or lung.

**Clinical Pathology findings**—Sporadic elevations in blood urea nitrogen (BUN), anion gap, and bilirubin were present only in serovar Pomona infected dogs. BUN levels were elevated in two dogs on day 10 PI and a single dog on each of days 14 and 20 PI. There were not concomitant elevations in creatinine. Elevation in Dbili, Tbili, GGT and ALP were noted in 4 dogs on day 14 PI and a single remaining dog (from this group of 4) that was necropsied on day 20 PI. Elevations in ALP ranged from 834 IU/L to 1413 IU/L (reference interval 20-115 IU/L). Platelets from culture positive dogs were decreased from baseline values on days 9, 11, and 13 PI (Fig. 8). A single dog infected with serovar Pomona had a slightly prolonged PTT on day 10 PI (21.1 sec; reference interval 8.9-18.7 sec). On day 14 PI, 2 serovar Pomona inoculated dogs had glucose (+) and bilirubin (3+) in the urine. Results from CBC

and serum biochemistry profiles in serovar Bratislava inoculated dogs did not differ from control dogs.

**Serology**—MAT titers of 1:100 were detected in two serovar Bratislava inoculated dogs at day 20 PI. Two serovar Pomona inoculated dogs had MAT titers of 1:200 and 1:800, respectively, at 20 days PI. The dog with a 1:800 titer to serovar Pomona at day 20 PI also had a 1:200 titer at day 14 PI, but no other agglutinating antibody titers of 1:25 or greater were noted in any dogs.

Figure 8—There was a transient decrease in platelet numbers in clinically ill dogs at days 9-13 post-inoculation when compared to control dogs. Average platelet counts for infected dogs are expressed as a percent of pooled control samples.



## DISCUSSION

A canine model was used to study leptospiral infection by *L. interrogans* serovars Pomona and Bratislava. Leptospiral infection was confirmed in all except one serovar

Pomona inoculated dog by positive culture and immunofluorescence tests. Serovar Pomona infected dogs had clinical signs including lethargy, loose feces with flecks of blood, and fever. At days 10, 14, and 20 PI, there was gross and microscopic evidence of hemorrhage of kidney and lung in serovar Pomona inoculated dogs that was associated with a mild transient decrease in platelet numbers. There was no evidence of infection in any dogs inoculated with this canine-derived serovar Bratislava isolate. Dogs infected with serovar Pomona had unique clinical signs, clinicopathologic abnormalities, and lesion patterns when compared to infection with *Leptospira kirschneri* serovar Grippotyphosa.<sup>26</sup> Serovar Grippotyphosa infection manifested as severe renal and hepatic failure resulting in severe biochemical abnormalities and death by 12 days PI. Serovar Pomona infected dogs frequently had evidence of hemorrhage in lung and kidney, but fewer biochemical abnormalities, even though histologic lesions in kidney were more severe than those in serovar Grippotyphosa infected dogs.

The presence of hemorrhage was supported by gross, histopathologic, and clinical pathologic data. Hemorrhage in serovar Pomona infected dogs was associated with sporadic increases in BUN, but were not accompanied by elevations in creatinine that can indicate gastrointestinal hemorrhage with absorption of blood. One of the dogs with elevated BUN had loose feces with flecks of blood prior to necropsy at day 10. A second dog with elevated BUN had large amounts of digested blood within the intestine at necropsy.

Renal lesions were present in all serovar Pomona infected dogs. Interstitial nephritis increased in severity over the time course of disease, but was not associated with indicators of renal failure as in the case of inoculation of dogs with *Leptospira kirschneri* serovar Grippotyphosa.<sup>26</sup> Since most infected dogs had BUN and creatinine within the reference



intervals, this indicates that greater than 25% of renal function remained, but does not exclude the possibility of renal disease. Hyaline droplets in the proximal convoluted tubules, formed when resorption by the cell outpaces the digestion of protein during pinocytotic vesicle fusion with lysosomes, suggest plasma protein leakage from abnormal glomerular capillaries or abnormal protein processing by tubular epithelium. Glucosuria without hyperglycemia, which occurred in 2 dogs at day 14 PI, further suggests a renal tubular dysfunction.

Clinical pathology data and histopathologic examination in severely affected dogs suggested cholestasis on days 14 and 20 PI. Elevated total and direct bilirubin and markedly elevated ALP were noted in 4 dogs. These abnormalities were associated with histologic evidence of dense perivascular infiltrates of lymphocytes, plasma cells, macrophages, and neutrophils in portal areas, bile plugs in bile canaliculi, and multifocal areas of hepatic necrosis that corresponded to the multifocal raised white areas noted grossly.

Several diagnostic methods were utilized to confirm leptospiral infection, and infection was confirmed in 11/12 serovar Pomona inoculated dogs. Blood culture was the most sensitive method of detecting infection by serovar Pomona at days 7 or 8 PI. PCR samples collected at the day 7 PI necropsies were negative, but PCR was attempted on renal tissue only. Only one dog had a MAT titer that would be diagnostic for leptospirosis by published standards of 1:800 to 1:3200 used in retrospective studies as evidence of leptospiral infection.<sup>14, 15</sup> At 20 days PI, one serovar Pomona inoculated dog had a MAT titer of 1:200 and another had a titer of 1:800.

Serovar Bratislava infection was not detected in any dog by immunofluorescence testing, culture, immunohistochemistry, or PCR. The inability of this canine derived isolate

to infect or cause disease in dogs may be a result of change in expression of virulence factors due to passage in culture. The organisms grew rapidly in culture indicating adaptation to culture conditions that often is associated with loss of virulence.<sup>27</sup> Later, this isolate was used to challenge hamsters since they are highly susceptible to most pathogenic isolates of *Leptospira*, but there were no clinical signs (Alt, 2001 unpublished data). Infection with serovar Bratislava has been demonstrated in dogs in Great Britain with reproductive failure or renal disease.<sup>28, 29</sup>

---

<sup>a</sup> Marshall Farms, North Rose, NY

<sup>b</sup> PLM 5, Intergen Co., Purchase, NY

<sup>c</sup> DNeasy tissue kit, Qiagen, Valencia, CA

<sup>d</sup> BSA; Sigma, St. Louis, MO

<sup>e</sup> Fisher Chemicals, Fairlawn, NJ

<sup>f</sup> NBS, donkey; Vector Laboratories Inc., Burlingame, CA

<sup>g</sup> Vector Elite ABC Kit; 1:600; Vector Laboratories Inc., Burlingame, CA

<sup>h</sup> NOVA RED, Vector Laboratories, Burlingame, CA

## REFERENCES

1. Yang CW, Wu MS, Pan MJ. Leptospirosis renal disease. *Nephrol Dial Transplant* 2001; 16 Suppl 5: 73-77.
2. Bolin CA. Diagnosis of leptospirosis: A reemerging disease of companion animals. *Semin Vet Med Surg (Small Anim)* 1996; 11: 166-171.
3. Ward MP, Glickman LT, Guptill LF. Prevalence of and risk factors for leptospirosis among dogs in the United States and Canada: 677 cases (1970-1998). *J Am Vet Med Assoc* 2002; 220: 53-58.
4. Navarro CE, Kociba GJ, Kowalski JJ. Serum biochemical changes in dogs with experimental *Leptospira interrogans* serovar Icterohaemorrhagiae infection. *Am J Vet Res* 1981; 42: 1125-1129.

5. Navarro CE, Kociba GJ. Hemostatic changes in dogs with experimental *Leptospira interrogans* serovar Icterohaemorrhagiae infection. *Am J Vet Res* 1982; 43: 904-906.
6. Monlux W. Leptospirosis. III. The clinical pathology of canine leptospirosis. *Cornell Vet* 1948; 38: 109-121.
7. Monlux W. Leptospirosis. IV. The pathology of canine leptospirosis. *Cornell Vet* 1948; 38: 199-208.
8. McIntyre WIM, Montgomery GL. Renal lesions in *Leptospira canicola* infection in dogs. *J Pathol Bact* 1952; 64: 145-160.
9. Taylor PL, Hanson LE, Simon J. Serologic, pathologic, and immunologic features of experimentally induced leptospiral nephritis in dogs. *Am J Vet Res* 1970; 31: 1033-1049.
10. Low DG, Hiatt CW, Gleiser CA, et al. Experimental canine leptospirosis I. *Leptospira icterohaemorrhagiae* infections in immature dogs. *J Infect Dis* 1956; 98: 249-259.
11. Low DG, Bergman EN, Hiatt CW, et al. Experimental canine leptospirosis II. Renal function studies. *J Infect Dis* 1956; 98: 260-265.
12. Adin CA, Cowgill LD. Treatment and outcome of dogs with leptospirosis: 36 cases (1990-1998). *J Am Vet Med Assoc* 2000; 216: 371-375.
13. Kalin M, Devaux C, DiFruscia R, et al. Three cases of canine leptospirosis in Quebec. *Can Vet J* 1999; 40: 187-191.
14. Birnbaum N, Barr SC, Center SA, et al. Naturally acquired leptospirosis in 36 dogs: Serological and clinicopathological features. *J Small Anim Pract* 1998; 39: 231-236.
15. Rentko VT, Clark N, Ross LA, et al. Canine leptospirosis. A retrospective study of 17 cases. *J Vet Intern Med* 1992; 6: 235-244.
16. Boutilier P, Carr A, Schulman RL. Leptospirosis in dogs: A serologic survey and case series 1996 to 2001. *Vet Ther* 2003; 4: 178-187.
17. Cole JR, Sulzer CR, Pursell AR. Improved microtechnique for the leptospiral microscopic agglutination test. *Appl Microbiol* 1973; 25: 976-980.
18. Thiermann A, McClellan R, Hill H. Improved techniques for the isolation of leptospire from swine abortion cases, in *Proceedings. 27th Annual Proceedings, Amer. Assn. Veterinary Laboratory Diagnosticians* 1984; 233-244.
19. Nielsen JN, Cochran GK, Cassells JA, et al. *Leptospira interrogans* serovar bratislava infection in two dogs. *J Am Vet Med Assoc* 1991; 199: 351-352.
20. Ellis WA, Montgomery J, Cassells JA. Dihydrostreptomycin treatment of bovine carriers of *Leptospira interrogans* serovar hardjo. *Res Vet Sci* 1985; 39: 292-295.
21. Johnson RC, Harris VG. Differentiation of pathogenic and saprophytic leptospire I. Growth at low temperatures. *J Bacteriol* 1967; 94: 27-31.
22. Thiermann AB, Handsaker AL, Foley JW, et al. Reclassification of North American leptospiral isolates belonging to serogroups mini and sejroe by restriction endonuclease analysis. *Am J Vet Res* 1986; 47: 61-66.
23. Zuerner RL, Bolin CA. Differentiation of *Leptospira interrogans* isolates by is1500 hybridization and PCR assays. *J Clin Microbiol* 1997; 35: 2612-2617.
24. Bolin CA, Thiermann AB, Handsaker AL, et al. Effect of vaccination with a pentavalent leptospiral vaccine on *Leptospira interrogans* serovar hardjo type hardjo-bovis infection of pregnant cattle. *Am J Vet Res* 1989; 50: 161-165.

25. Shang ES, Exner MM, Summers TA, et al. The rare outer membrane protein, OmpL1, of pathogenic *Leptospira* species is a heat-modifiable porin. *Infect Immun* 1995; 63: 3174-3181.

26. Greenlee JJ, Bolin C, Alt DP, et al. Clinical and pathologic comparison of acute canine leptospirosis caused by two strains of *Leptospira kirschneri* serovar Grippotyphosa. *Am J Vet Res* 2003; manuscript submitted.

27. Thiermann AB. Effect of cyclophosphamide treatment on clinical and serologic response of rats to infection with *Leptospira interrogans* serovar Icterohaemorrhagiae. *Am J Vet Res* 1980; 41: 1655-1658.

28. Thomas S. Leptospirosis apparently due to *Leptospira bratislava* in a dog. *Vet Rec* 1980; 106: 178-179.

29. van den Broek AHM, Thrusfield MV, Dobie GR, et al. A serological and bacteriological survey of leptospiral infection in dogs in Edinburgh and Glasgow. *J Small An Pract* 1991; 32: 118-124.

#### **ACKNOWLEDGEMENTS**

The authors thank Rick Hornsby and the National Animal Disease Center Leptospirosis Group for sharing their expertise in techniques for leptospiral culture and detection and Stacy Friesen for her technical assistance in immunohistochemical staining.

**CHAPTER 4. *LEPTOSPIRA INTERROGANS* SEROVAR POMONA  
INFECTION IN GUINEA PIGS AND *IN VITRO* EVIDENCE OF  
LEPTOSPIRE BINDING OF PLATELETS**

A manuscript prepared for submission to *Comparative Clinical Pathology*

J.J. GREENLEE<sup>1</sup>, D.P. ALT<sup>2</sup>, T. MARSHALL<sup>1</sup>, R.L. ZUERNER<sup>2</sup>, AND C.B. ANDREASEN<sup>1</sup>

<sup>1</sup>*Department of Veterinary Pathology, College of Veterinary Medicine, Iowa State University, Ames, IA, USA*

<sup>2</sup>*Bacterial Diseases of Livestock Research Unit, National Animal Disease Center, Agricultural Research Service, USDA, Ames, IA, USA*

**ABSTRACT**

Guinea pig inoculations and *in vitro* platelet binding assays were done to examine the pathogenesis of hemorrhage in leptospirosis. Thirty juvenile guinea pigs were inoculated intraperitoneally with *Leptospira interrogans* serovar Pomona type kennewicki (n=20) or an equal volume of sterile culture media (n=10). Guinea pigs were sequentially necropsied on days 2-6 post-inoculation (PI). CBC's, biochemistry profiles, and clotting assays (prothrombin time, partial thromboplastin time, D-dimers) were done during the course of disease and correlated with gross and histologic lesions. Tissue samples were taken for culture, immunofluorescence tests, and immunohistochemical staining to confirm infection. The infected guinea pigs had gross and histologic lesions beginning at 3 days PI. On days 3-6 PI, the infected guinea pigs had decreased platelet counts relative to controls, multifocal hepatic necrosis, and hemorrhage in lung, kidney, liver, and heart. Microtiter assays and fluorescent microscopy were done to determine if leptospires bind guinea pig platelets.

Leptospire bound platelet monolayers, but not empty wells or control wells containing fibrinogen or platelet poor plasma. Binding was not inhibited by anti CD41 antibody or 5 mM EDTA suggesting binding is not integrin mediated. Leptospire retained the ability to bind platelet monolayers after incubation in gelatin or dextran sulfate, which block fibronectin and glycosaminoglycan binding, respectively.

## INTRODUCTION

Hemorrhage occurs in cases of leptospirosis in human beings<sup>1,2</sup> and dogs,<sup>3</sup> especially in the lungs and kidneys. The cause of this hemorrhage is not known, but hypotheses include physical damage to small vessels by leptospire, disseminated intravascular coagulopathy,<sup>4</sup> and the action of leptospiral toxins on the endothelium.<sup>5</sup> Hemorrhage has been associated with thrombocytopenia,<sup>1</sup> but specific interactions between leptospire and platelets have not been investigated.

For other spirochetes, namely *Borrelia burgdorferi* and *Borrelia hermsii*, direct interactions between platelets and spirochetes have been demonstrated. *Borrelia burgdorferi* has been shown to bind activated platelets in an integrin  $\alpha\text{IIb}\beta\text{3}$  (glycoprotein IIb IIIa) dependent manner,<sup>6,7</sup> and through an alternate cell surface proteoglycan mediated pathway.<sup>8</sup> Platelet binding plays a role in the thrombocytopenia associated with relapsing fever caused by *Borrelia hermsii* since the bacterium is able to activate platelets and promote further binding.<sup>9</sup>

Guinea pigs are a commonly used model for leptospirosis studies, and previous studies have demonstrated hemorrhage in experimental cases.<sup>10,11</sup> *Leptospira interrogans* serovar Pomona has not been thoroughly investigated in a guinea pig model, nor have direct

interactions between leptospire and platelets been described. While a decrease in platelet number is a common feature of leptospirosis, the correlation between platelet number, platelet function, and onset of clinical signs post-inoculation remains ill defined.<sup>5, 12</sup>

The mechanism of hemorrhage in leptospirosis is unknown and the affect of leptospire on platelets requires study. These experiments were designed to determine if hemorrhage occurs in a guinea pig model of serovar Pomona infection, and to test the hypothesis that leptospire interact directly with blood platelets *in vitro*. Experiment one was performed to determine if hemorrhage is a consequence of serovar Pomona infection in guinea pigs as it is in dogs. The objective of experiment two was to obtain guinea pig platelets for *in vitro* examination of leptospire and platelet binding through microtiter assays and fluorescent microscopy. We conclude from these experiments that hemorrhage occurs in guinea pigs infected with serovar Pomona and we demonstrate a direct interaction of leptospire and platelets *in vitro*.

## **MATERIALS AND METHODS**

### **Experiment #1**

**Animals and experimental design**—Guinea pigs (n=30) were housed one per cage at Iowa State University in biosafety level-2 rooms maintained at a constant temperature and humidity. Cages were cleaned once daily and food and water were available at all times and freshened twice daily. Guinea pigs were randomly divided into four groups: controls (n=10) and principals inoculated with either  $10^6$  (n=5),  $10^7$  (n=5), or  $10^8$  (n=10) *L. interrogans* serovar Pomona type kennewicki. Inocula consisted of either 1 ml sterile culture media (controls) or the appropriate number of leptospire in 1 ml administered into the peritoneal

cavity. All animal experiments were performed with the approval of the Iowa State University Committee on Animal Care.

**Bacterial strains and growth conditions**—*L. interrogans* serovar Pomona type kennewicki strain RM 211 was isolated at the USDA/ARS-National Animal Disease Center from neonatal kidney and liver tissues from an Iowa swine herd that were submitted to the Veterinary Diagnostic Laboratory at Iowa State University.<sup>13</sup> The herd had a history of 25 of 75 pregnancies resulting in abortion or stillbirth. Leptospire were cultured in Tween 80/40 semisolid media at 29 C, counted with a Petroff-Hausser Counting Chamber (Hausser Scientific, Horsham, PA), and diluted to 10<sup>8</sup>, 10<sup>7</sup>, or 10<sup>6</sup> organisms per ml in commercial Polysorbate Leptospira Medium 5 (PLM 5, Intergen Co., Purchase, NY). Aliquots of 1 ml were loaded into syringes for intraperitoneal injection.

**Bacterial colonization**—Immunohistochemistry, bacterial culture, or immunofluorescence assays were used to confirm bacterial colonization in inoculated guinea pigs. Kidney, lung, liver, and heart were examined by immunohistochemistry using a rabbit polyclonal antibody to serovar Pomona. Briefly, 5 µm sections were cut, placed on positively charged slides, and deparafinized with xylene and ethanol by standard procedures. Slide mounted tissue sections were rinsed in potassium phosphate buffered solution (KPBS; 0.15 M NaCl, 0.034 M K<sub>2</sub>HPO<sub>4</sub>, 0.017 M KH<sub>2</sub>PO<sub>4</sub>, pH 7.4), and antigen retrieval was performed by incubating slides for 7 minutes in 37 C KPBS with 0.1% trypsin and 0.1% CaCl<sub>2</sub>. After 2 rinses in KPBS, endogenous peroxidase activity was eliminated by incubation in 0.3% hydrogen peroxide solution in KPBS for 30 minutes. The sections were then incubated for two hours in blocking solution (KPBS with 1% bovine serum albumin, 0.4% Triton X-100, and 1.5% normal blocking serum (NBS, donkey; Vector Laboratories Inc.,



Burlingame, CA 94010), and incubated overnight at room temperature (24°C) in primary antiserum. On the following day, tissue sections were rinsed in KPBS with 0.2% Triton X-100 and incubated in an appropriate biotinylated secondary antibody for two hours at room temperature, rinsed, and incubated in Horseradish Peroxidase-Avidin-Biotin Complex (Vector Elite ABC Kit; 1:600; Vector Laboratories Inc., Burlingame, CA 94010) for 1 hour at room temperature. Enzyme reactions were developed with a substrate kit (NOVA RED, Vector Laboratories, Burlingame, CA 94010) producing a red reaction. The reaction was terminated in successive rinses of 0.9% NaCl solution. Slides were counterstained with hematoxylin, dehydrated through graded alcohols, and coverslipped.

Samples for blood cultures were taken at necropsy. In addition, liver and kidney samples of approximately 1 gram were obtained and processed for isolation of leptospire. Three media were used to increase the chances of isolation. First, Tween 80/Tween 40/lactalbumin hydrolysate was used as previously described<sup>14</sup> with slight modifications: 5-fluorouracil was used at a rate of 100µg/ml and naladixic acid was not used. Second, Ellinghausen-McCullough-Johnson-Harris (EMJH) semisolid media was used as previously described<sup>15</sup> with the modifications of 10% BSA, 100 µg/ml 5-fluorouracil, and 1% rabbit serum. Finally, PLM-5 was used with the addition of purified agar and 100µg/ml 5-fluorouracil. Cultures were incubated at 29° C for 6 months. Darkfield examination was performed at 1, 2, 4, 6, and 8 weeks and at 3, 4, 5, and 6 months. If cultures became contaminated, approximately 1 ml was filtered through a 0.22 µm filter into new medium. Representative isolates were identified by restriction endonuclease analysis of chromosomal DNA.<sup>16</sup>

Samples of urine, kidney, and liver were stained with fluorescein-labeled rabbit anti-leptospiral conjugate as previously described.<sup>17</sup> Leptospire were identified by typical size, morphology, and fluorescence when examined by incident light fluorescence microscopy.

**Necropsy and sample collection**—Serial necropsies were done on days 2-6 post inoculation (PI). Each day two guinea pigs from the control and  $10^8$  groups and one guinea pig from each of the  $10^6$  and  $10^7$  groups were necropsied. Animals were anesthetized using a xylazine (10 mg/kg) and ketamine (70 mg/kg). Blood was drawn from the heart for clotting assays (PT, PTT, and D-dimer), CBC, and serum biochemistry panels including sodium, potassium, chloride, total  $\text{CO}_2$  ( $\text{TCO}_2$ ), calcium, phosphorus, blood urea nitrogen, creatinine, glucose, total protein, albumin, alanine aminotransferase (ALT), alkaline phosphatase (ALP),  $\gamma$ -glutamyltransferase (GGT), creatine kinase (CK), direct bilirubin (Dbili), total bilirubin (Tbili), and anion gap. During necropsy, liver, kidney, and urine were taken aseptically for culture and immunofluorescence testing. Samples of kidney, liver, lung, hepatic lymph node, adrenal gland, spleen, heart, pancreas, stomach, small intestine, cecum, colon, bladder, bone marrow, and thymus gland were collected into 10% neutral buffered formalin.

**Histopathology**—Samples were placed in 10% neutral buffered formalin for 24 hours, then embedded in paraffin, sectioned at 5  $\mu\text{m}$  (3 $\mu\text{m}$  for kidney, spleen, lymph node, and bone marrow), mounted on glass slides and stained with hematoxylin and eosin (H&E) according to standard histologic procedures.

## **Experiment #2**

**Animals**—All animal protocols were approved by the Iowa State University Committee on Animal Care. Blood was collected from female guinea pigs (n=8) weighing 250 to 400g. Guinea pigs were anesthetized with 10 mg/kg xylazine in combination with 70

mg/kg ketamine injected IP, and 9 volumes blood were drawn with a 22-gauge needle from the heart into tubes containing 1 volume 0.105 M sodium citrate. After obtaining 12-15 ml of blood, the animals were euthanized.

**Preparation of Gel Filtered Platelets**—Blood with sodium citrate anticoagulant was transferred into polypropylene tubes, and centrifuged for 15 min. at 140 x g to obtain platelet rich plasma (PRP) . The PRP was filtered through an agarose bead column<sup>18</sup> (Sephacose 2 B Sigma, St. Louis, MO) equilibrated with modified HEPES-Tyrode's buffer (2 mM HEPES, 137 mM NaCl , 12mM NaHCO<sub>3</sub>, 1mM MgCl<sub>2</sub>, 2.7 mM KCL, 5.6 mM dextrose, 0.35% bovine albumin at pH 7.35), and adjusted to flow at approximately 1 ml/min. Platelet fractions were adjusted to 10<sup>8</sup>/ml and activated with 0.2 U/ml thrombin (Sigma Chemical, St. Louis, MO) for 20 minutes at room temperature. Platelet poor plasma (PPP) was obtained by centrifuging the remaining sample at 1800 x g for 15 minutes.

**Preparation of bacteria**—*L. interrogans* serovar Pomona type kennewicki strain RM211 was grown in BAP-80 liquid medium<sup>19</sup> or PLM-5 at 29 C. Approximately 14 ml of active liquid culture media was divided into 1 ml portions in microcentrifuge tubes and centrifuged at 14,000 g for 8 minutes. The supernatant was poured off, and the pellet was resuspended in PBS and centrifuged again at 14,000 g for 8 minutes. The supernatant was removed and the pellet resuspended in a mixture of 2:1 BAP-80 medium to PBS, serial dilutions performed, and the bacteria were counted using a Petroff-Hausser Counting Chamber. A 10<sup>9</sup> leptospire/ml concentration was used for the slide preparations and a 10<sup>8</sup> leptospire/ml dilution was used for the microtiter assays.

**Microtiter assays of platelet-leptospire binding**—Platelet-spirochete binding was assessed in an assay similar to that previously described<sup>7</sup> using fluorescent DNA staining to detect bound leptospire, since platelets are anuclear and devoid of DNA. Activated platelets ( $10^7$  per well) were added to black polystyrene microtiter plates (Cliniplate, Thermo-Labsystems; Fisher Scientific, Hanover Park, IL) and centrifuged at room temperature for 15 min at 425 x g. Platelet monolayers were covered with approximately  $5 \times 10^6$  leptospire and centrifuged at 1,200 x g for 20 minutes to facilitate leptospire-platelet contact. A 30 min incubation at room temperature allowed for stable binding of bacteria. Unbound bacteria were removed by washing three times with PBS. Bound spirochetes and platelets were fixed by addition of 3% paraformaldehyde in PBS (50  $\mu$ l per well). The paraformaldehyde was allowed to dry overnight at room temperature, and the cells were permeabilized by incubating the cells for 10 min at  $-20$  C in 50 $\mu$ l/well prechilled methanol. After the methanol was removed, plates were allowed to dry at room temperature. The fluorescent DNA stain 4',6-diamidino-2-phenylindole (DAPI; Molecular Probes, Eugene, OR) was used at 0.1  $\mu$ g/ml in PBS with 50  $\mu$ l added to each well, and the plates incubated for 10 min at room temperature in the dark. After two washes in PBS and addition of 50  $\mu$ l of fresh PBS per well, fluorescence was quantitated by a microplate spectrofluorometer (SPECTRAMax GEMINI XS, Molecular Devices Corporation, Sunnyvale CA) at an excitation wavelength of 355 nm and an emission wavelength of 460 nm. Fluorescence of leptospire only wells was compared to that of platelet monolayers with an equal number of applied leptospire alone or after incubation with various potential binding inhibitors. Attempts to inhibit platelet-leptospire binding were made with anti-CD41a (P2 Clone, Beckman Coulter, Miami, FL), a function blocking antibody that reacts with the  $\alpha$ IIb subunit of the intact integrin

$\alpha\text{IIb}\beta_3$ , and 5 mM EDTA, a non-specific integrin blocker. In addition, leptospire were incubated in dextran sulfate to block sites for cell membrane proteoglycan binding<sup>8</sup> or gelatin to block fibronectin binding sites.<sup>20</sup> PPP and 70  $\mu\text{g}/\text{well}$  fibrinogen were used as controls for non-specific protein binding. All assays were performed in triplicate on platelets derived from three or more guinea pigs.

**Microscopy**—Samples for fluorescent microscopy were prepared by placing 100  $\mu\text{l}$  containing  $1 \times 10^7$  platelets or  $1 \times 10^7$  activated platelets and 100  $\mu\text{l}$  containing  $1 \times 10^8$  leptospire in a microcentrifuge tube. After a 20 min incubation at room temperature, samples were fixed by adding 100  $\mu\text{l}$  of a 2% glutaraldehyde and 2% paraformaldehyde solution. Ten  $\mu\text{l}$  of the sample was used for smears on polylysine coated slides for fluorescent microscopy. Air dried slides were rinsed with PBS and incubated in blocking solution for 90 minutes (PBS with 5% Donkey serum (Jackson ImmunoResearch, West Grove, PA, USA 19390) at room temperature. Slides were subsequently incubated in anti-CD41(P2 Clone, Beckman Coulter, Miami, FL 33196; 1:200) diluted in blocking solution for 12 hours at room temperature. After incubation in primary antibody, slides were rinsed in PBS and incubated in secondary antibody for 90 minutes at room temperature (Donkey anti-mouse IgG-Alexa 488, 1:200; Molecular Probes, Eugene, OR). After rinsing in PBS, slides were incubated in DAPI (Molecular Probes, Eugene, OR; 0.1  $\mu\text{g}/\text{ml}$  PBS) rinsed in PBS and coverslipped with Vectashield mounting medium (Vector Laboratories, Burlingame, CA). Alexa 488 and DAPI fluorescence was viewed with a Nikon ES800 microscope equipped with fluorescence detection. Images were captured with a Retiga 1300 CCD camera driven by Open Lab Software (Improvision).

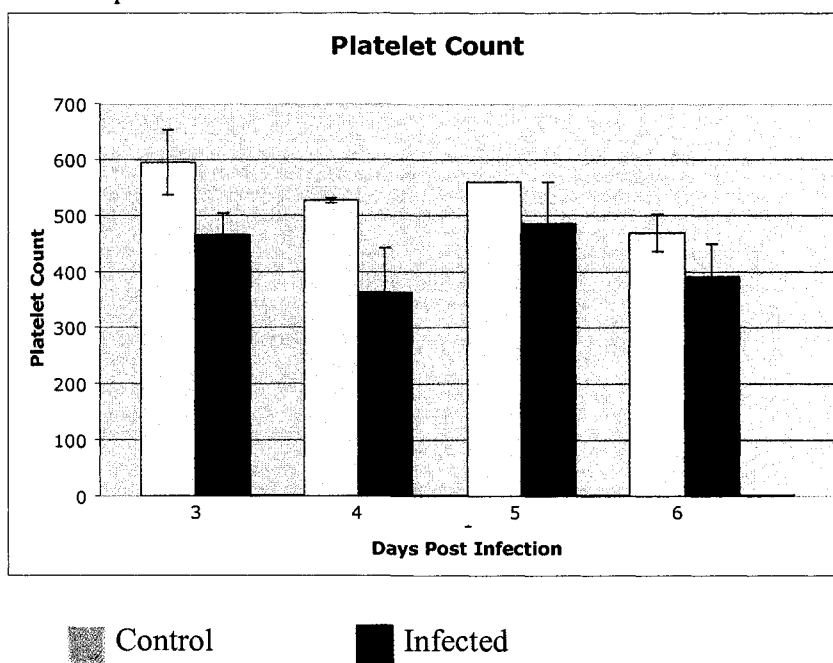
## RESULTS

### Experiment 1

#### Confirmation of infection and biochemical, gross, and histopathologic lesions—

The presence of leptospire was confirmed in all inoculated guinea pigs by culture, immunohistochemistry, or immunofluorescence testing (data not shown). No clinical signs were noted in any inoculated guinea pigs, but average weight gain was less in inoculated animals ( $10^6$  (50.5g),  $10^7$ (24g),  $10^8$ (27.5g)) when compared to controls (71g). On days 3-6 PI the infected group had a lower average platelet count than the control group (Fig. 1).

Figure 1. At days 3 and 4 PI, there is a transient decrease in the platelet count of inoculated guinea pigs when compared to control.



No other significant differences were noted in CBC or serum biochemistry results from inoculated guinea pigs. Beginning at day 3 PI, infected guinea pigs had gross lesions including multifocal 1-2 mm slightly raised, round white foci throughout the liver (hepatic necrosis (13/16)), splenomegaly (8/16), and pulmonary hemorrhage (8/16) (Fig 2).

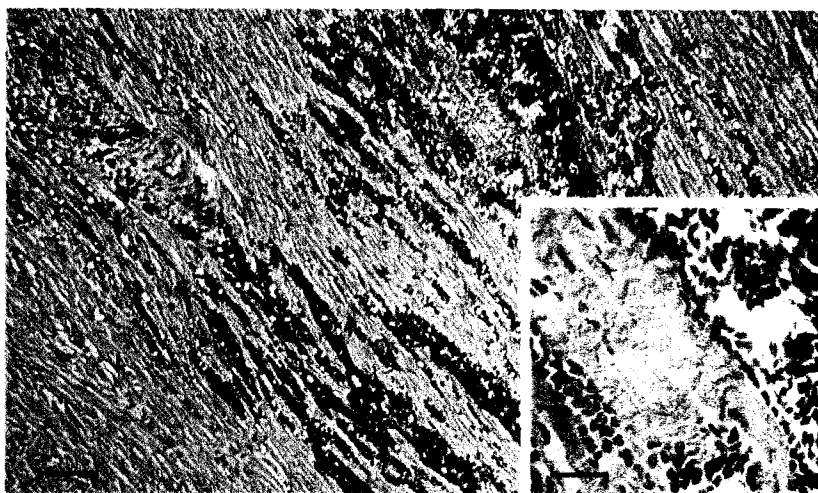
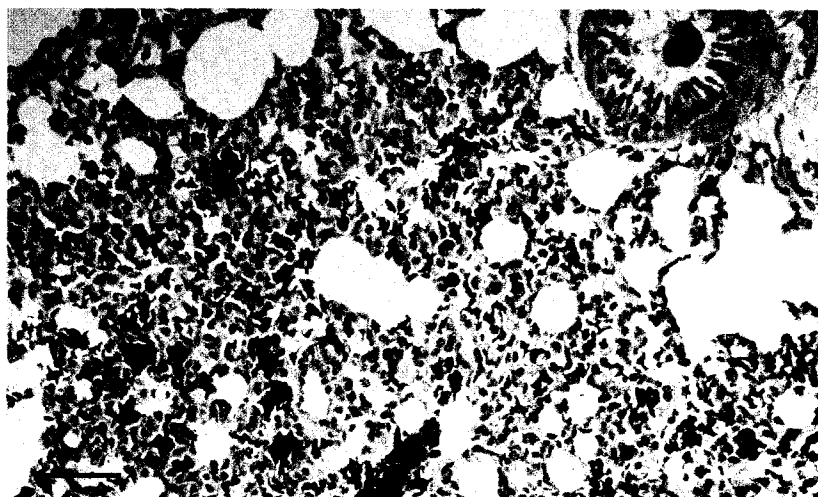
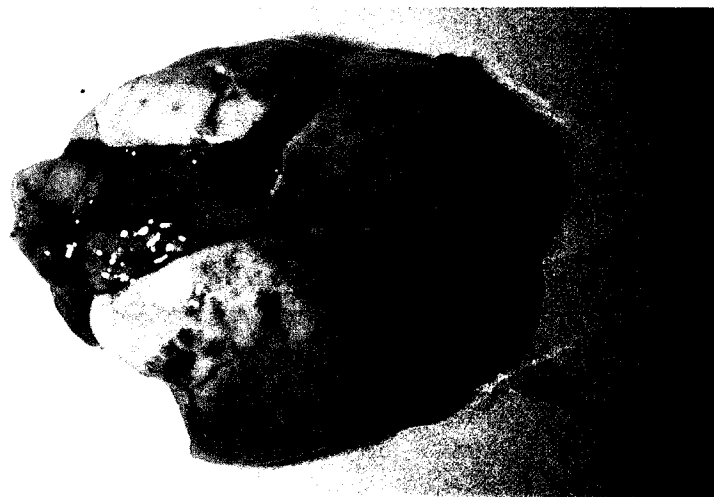## FIGURE LEGENDS

Figure 2- Gross image of the lungs of a *Leptospira interrogans* serovar Pomona strain RM 211 inoculated guinea pig at 3 days PI. There are multifocal to coalescing pulmonary hemorrhages.

Figure 3- Photomicrograph of a section of lung from a serovar Pomona inoculated guinea pig at 3 days PI. Multiple alveoli are filled with blood. H&E stain. Bar = 50  $\mu\text{m}$

Figure 4- Photomicrograph of a section of heart from a serovar Pomona inoculated guinea pig at 3 days PI. Cardiac myocytes are widely separated by blood and are multifocally necrotic. Inset: Necrotic cardiac myocytes are swollen and pale and lack cross striations. H&E stain. Bar = 100  $\mu\text{m}$ ; Inset=30  $\mu\text{m}$

2





No histologic lesions were noted in guinea pigs at day 2 PI. In guinea pigs examined on days 3-6 PI, hemorrhages were present in lung (12/16) (Fig. 3), kidney (6/16), heart (10/16) (Fig. 4), and sporadically in pancreas, adrenal gland, lymph node, meninges, and perirenal adipose tissue of infected guinea pigs. Hemorrhage in lymph nodes and lung was associated with phagocytosis of erythrocytes by macrophages (erythrophagocytosis). Mixed inflammatory infiltrates of lymphocytes, macrophages, plasma cells, and neutrophils occurred in the renal cortical interstitium and pelvis and sporadically in interlobular and perivascular areas of the pancreas and within the heart. Interstitial nephritis was subtle except for day 6 PI where interstitial infiltrates were associated with lesions in adjacent tubules, including flattened tubular epithelium with occasional apoptotic cells. Lesions in the liver included portal infiltrates of lymphocytes and neutrophils (11/20), and random multifocal areas of hepatic coagulative necrosis (15/20). The enlargement of the spleen in several guinea pigs was associated with lymphoid hyperplasia, congestion, and hemorrhage.

## **Experiment 2**

**Microtiter binding assays and fluorescent microscopy**—After the addition of a known number of leptospire, fluorescence levels of DAPI stained microtiter wells were measured (Fig. 4). When leptospire were applied directly to empty wells or wells containing fibrinogen or platelet poor plasma, fluorescence levels were similar to wells containing only buffer. When leptospire were applied to platelet monolayers fluorescence levels were markedly increased. Fluorescent levels were similar after incubation of platelets with anti CD41 antibody or EDTA (data not shown), or incubation of leptospire with gelatin or dextran sulfate.

## FIGURE LEGEND

Figure 5-Images from right to left illustrate CD41 fluorescence for platelet integrin  $\alpha\text{IIb}\beta_3$ , DAPI fluorescence of leptospiral DNA, and an overlay image, respectively. In non-activated platelet samples (top row), platelets are singular without apparent association with leptospores. In activated platelet samples (bottom row), platelets and leptospores form large aggregates.


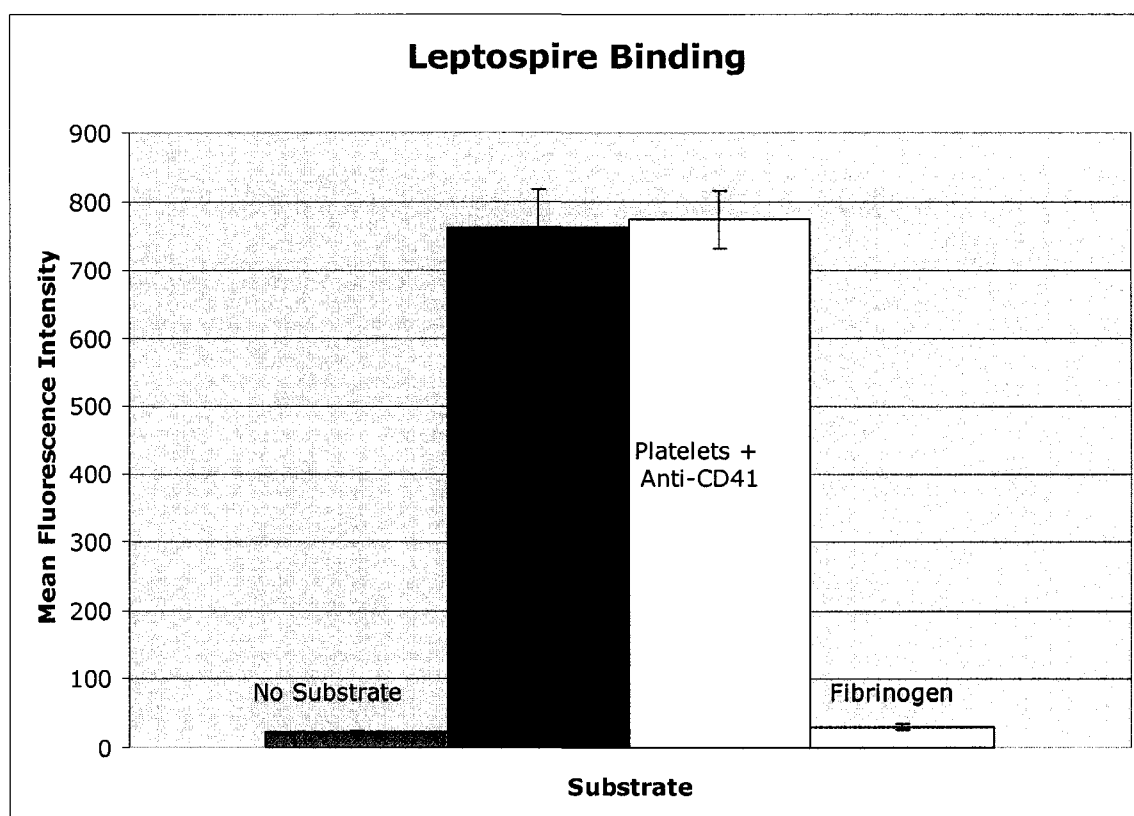


Figure 4. The fluorescence intensity of DAPI stained leptospiral DNA is plotted for wells containing no substrate; activated platelets only; activated platelets treated with anti-CD41, an integrin  $\alpha\text{II}_b\beta_3$  blocker; and fibrinogen, a control for non-specific protein binding.



By fluorescent microscopy, large numbers of leptospires were present around individual activated platelets or surrounding and within larger platelet aggregates (Fig 5). These aggregates did not occur in samples with non-activated platelets.

## DISCUSSION

Guinea pig inoculations and *in vitro* binding assays were done to assess the extent of hemorrhagic lesions in a guinea pig model of *Leptospira interrogans* serovar Pomona infection and to test the hypothesis that leptospires can bind platelets. Inoculation of guinea pigs with serovar Pomona causes hemorrhagic and inflammatory lesions in a variety of

tissues. *In vitro* binding assays showed enhanced binding of leptospire to microtiter wells with platelet monolayers when compared to binding of leptospire to wells without platelets or wells containing platelet poor plasma or fibrinogen. Fluorescence microscopy was used to further demonstrate leptospire binding of platelets.

Serovar Pomona in guinea pigs caused mild interstitial nephritis, hepatic necrosis, and inflammation in hepatic portal areas. Lesions were not associated with serum biochemical abnormalities, increased PTT or PT, or significant D-dimer titers. Platelet numbers in the infected group were mildly decreased days 3-6 PI, relative to the control group (Fig. 1). The decrease in platelet numbers corresponded with the appearance of hemorrhage. Although platelet numbers remained adequate for appropriate hemostasis, platelet functional ability is unknown.

Leptospire interacted with activated platelets as shown by leptospire binding to platelet monolayers. In contrast to *Borrelia*, significant blocking of binding did not occur after incubating the activated platelets with integrin  $\alpha\text{IIb}\beta_3$  blocking antibody, EDTA,<sup>6,7</sup> or incubating the leptospire in buffer containing dextran sulfate.<sup>8</sup> Gelatin blocks binding sites of fibronectin,<sup>20</sup> a component of platelet  $\alpha$  granules, but binding of leptospire to platelet monolayers was not inhibited by incubation with gelatin. These data suggest that platelet leptospire interactions are not mediated by binding through integrins or fibronectin, but multiple concentration studies were not done. Fluorescent microscopy was used to view contacts that platelets and leptospire make when incubated *in vitro*. When leptospire interact with activated platelets, clumping occurs and aggregates of leptospire and platelets form. The binding studies in this work suggest this is not integrin  $\alpha\text{IIb}\beta_3$  mediated.

There are several possible roles for direct interactions between platelets and leptospire in the pathogenesis of leptospirosis. First, leptospire binding to platelets could result in decreased platelet function via platelet clumping or covering surface receptors. This mechanism could be an important factor in leptospire induced hemorrhage. Second, binding of leptospire to platelets may facilitate infection by transporting leptospire to areas of endothelial damage, which may promote entry of leptospire into organ parenchyma. Also, in areas of platelet activation and endothelial damage bacterial binding to platelets adherent to the subendothelium may facilitate leptospire infiltration. Finally, clumps of platelets around individual or groups of leptospire could shield the bacteria from the immune system and allow spread of infection. Infectious strains of *Borrelia burgdorferi* bind platelets whereas noninfectious strains do not,<sup>7</sup> but experiments have not been done to determine binding properties of other pathogenic and saprophytic isolates of *Leptospira*.

Hemorrhagic lesions occur in guinea pigs experimentally inoculated with *Leptospira interrogans* serovar Pomona. In the absence of abnormal PT, PTT, and D-dimer assays, a potential pathogenesis for hemorrhage may involve platelet-endothelial-leptospire interaction. We have demonstrated that leptospire bind activated platelets *in vitro*. Further studies are needed to determine the specific mechanism of binding and quantitate the extent of binding *in vivo*.

## REFERENCES

1. Nicodemo AC, Del Negro G, Amato Neto V. Thrombocytopenia and leptospirosis. *Rev Inst Med Trop Sao Paulo* 1990; 32: 252-259.
2. Nicodemo AC, Duarte MI, Alves VA, et al. Lung lesions in human leptospirosis: Microscopic, immunohistochemical, and ultrastructural features related to thrombocytopenia. *Am J Trop Med Hyg* 1997; 56: 181-187.

3. Greenlee JJ, D.P. Zuerner, R.L. Bolin, C.A. Andreasen, C.B. Experimental canine leptospirosis caused by *Leptospira interrogans* serovars Pomona and Bratislava. Prepared for submission to *Am J Vet Res* 2003.
4. Sitprija V, Pipatanagul V, Mertowidjojo K, et al. Pathogenesis of renal disease in leptospirosis: Clinical and experimental studies. *Kidney Int* 1980; 17: 827-836.
5. Miller NG, Allen JE, Wilson RB. The pathogenesis of hemorrhage in the lung of the hamster during acute leptospirosis. *Med Microbiol Immunol* 1974; 160: 269-278.
6. Coburn J, Leong JM, Erban JK. Integrin alpha IIb beta 3 mediates binding of the Lyme disease agent *Borrelia burgdorferi* to human platelets. *Proc Natl Acad Sci U S A* 1993; 90: 7059-7063.
7. Coburn J, Barthold SW, Leong JM. Diverse Lyme disease spirochetes bind integrin alpha IIb beta 3 on human platelets. *Infect Immun* 1994; 62: 5559-5567.
8. Leong JM, Morrissey PE, Ortega-Barria E, et al. Hemagglutination and proteoglycan binding by the Lyme disease spirochete, *Borrelia burgdorferi*. *Infect Immun* 1995; 63: 874-883.
9. Alugupalli KR, Michelson AD, Barnard MR, et al. Platelet activation by a relapsing fever spirochaete results in enhanced bacterium-platelet interaction via integrin alpha IIb beta 3 activation. *Mol Microbiol* 2001; 39: 330-340.
10. De Brito T, Bohm GM, Yasuda PH. Vascular damage in acute experimental leptospirosis of the guinea-pig. *J Pathol* 1979; 128: 177-182.
11. da Silva JJ, Netto BA, Lilembaum W, et al. The hemorrhagic syndrome of leptospirosis: An experimental study in guinea pigs. *Rev Soc Bras Med Trop* 1995; 28: 169-177.
12. Edwards CN, Nicholson GD, Hassell TA, et al. Thrombocytopenia in leptospirosis: The absence of evidence for disseminated intravascular coagulation. *Am J Trop Med Hyg* 1986; 35: 352-354.
13. Thiermann A, McClellan R, Hill H. Improved techniques for the isolation of leptospires from swine abortion cases, in *Proceedings. 27th Annual Proceedings, Amer. Assn. Veterinary Laboratory Diagnosticians* 1984; 233-244.
14. Ellis WA, Montgomery J, Cassells JA. Dihydrostreptomycin treatment of bovine carriers of *Leptospira interrogans* serovar hardjo. *Res Vet Sci* 1985; 39: 292-295.
15. Johnson RC, Harris VG. Differentiation of pathogenic and saprophytic letospires. I. Growth at low temperatures. *J Bacteriol* 1967; 94: 27-31.
16. Thiermann AB, Handsaker AL, Foley JW, et al. Reclassification of North American leptospiral isolates belonging to serogroups mini and sejroe by restriction endonuclease analysis. *Am J Vet Res* 1986; 47: 61-66.
17. Bolin CA, Thiermann AB, Handsaker AL, et al. Effect of vaccination with a pentavalent leptospiral vaccine on *Leptospira interrogans* serovar hardjo type hardjo-bovis infection of pregnant cattle. *Am J Vet Res* 1989; 50: 161-165.
18. Timmons S, Hawiger J. Isolation of human platelets by albumin gradient and gel filtration. *Methods Enzymol* 1989; 169: 11-21.
19. Ellinghausen HM, W.G. Nutrition of *Leptospira pomona* and growth of 13 other serotypes: Fractionation of oleic albumin complex and a medium of bovine albumin and polysorbate 80. *Am J Vet Res* 1965; 26: 45-51.

20. Merien F, Truccolo J, Baranton G, et al. Identification of a 36-kda fibronectin-binding protein expressed by a virulent variant of *Leptospira interrogans* serovar icterohaemorrhagiae. *FEMS Microbiol Lett* 2000; 185: 17-22.

#### **ACKNOWLEDGEMENTS**

The authors thank Rick Hornsby for his valuable assistance in preparing leptospiral cultures and diagnostic samples and Stacy Friesen for her technical help in immunohistochemical staining.



## CHAPTER 5. GENERAL CONCLUSIONS

The purpose of the studies contained in this dissertation was to better understand the clinical and pathologic abnormalities caused by infections with *Leptospira kirschneri* serovar Grippotyphosa and *Leptospira interrogans* serovars Pomona and Bratislava. Dogs were inoculated with all serovars and additional studies were done with serovar Pomona in guinea pigs. The guinea pig model was used to study binding of leptospire to platelets *in vitro*.

In the first study, “Clinical and pathologic comparison of acute canine leptospirosis caused by two strains of *Leptospira kirschneri* serovar Grippotyphosa”, it was demonstrated that infection with serovar Grippotyphosa causes severe renal and hepatic failure. Biochemistry profiles were consistent with severe renal and hepatic insufficiency, and infected dogs had lesions in kidney, liver, and pancreas. The predominant renal lesions consisted of interstitial nephritis, tubular degeneration and necrosis, and tubular mineralization. Early hepatic lesions consisted of portal and perivascular infiltrates of lymphocytes and plasma cells. Dogs necropsied later had evidence of severe cholestasis: dissociation of hepatocytes from hepatic laminae, hepatic lipidosis, and bile plugs in bile canaliculi. Lesions are similar in dogs infected with strain 82, a canine derived isolate, and strain RM 52, a swine derived isolate. However, strain 82 caused disease in a greater number of dogs. Infections were confirmed in 11/12 strain 82 inoculated dogs; whereas, only 3/14 strain RM 52 inoculated dogs were confirmed to be infected.

In the second study, “Experimental canine leptospirosis caused by *Leptospira interrogans* serovars Pomona and Bratislava”, the disease model established in the first study was used to investigate two additional serovars of *Leptospira*. The serovar Bratislava isolate was obtained from a canine source,<sup>1</sup> but did not cause disease in dogs or hamsters in an

experimental setting. The swine derived isolate of serovar Pomona caused lethargy, fever, and diarrhea in infected dogs and was associated with inflammation and hemorrhage in dogs necropsied at days 10, 14, and 20 post-inoculation (PI). Hemorrhage occurred in kidney and lung and was most severe at 10 days PI. In some cases, interstitial infiltrates progressed to affecting 25-50% of the parenchyma at 20 days PI. As compared to serovar Grippotyphosa; however, there were no biochemical abnormalities suggestive of renal failure. Elevated BUN in the absence of elevated creatinine occurred in 2 cases, which suggests hemorrhage into the intestine and resorption of blood. Liver lesions in serovar Pomona infected dogs were consistent with cholestasis at 20 days PI, which was corroborated by markedly elevated hepatic enzymes (ALP and GGT). Similar to serovar Grippotyphosa, pancreatitis occurred in a lesser number of cases, which has been described as a manifestation of serovar Pomona in a pork abattoir worker.<sup>2</sup> Platelet counts were decreased in infected dogs when compared to controls, and a subset of samples was used to perform platelet aggregation studies. In infected dogs coagulation assays (PT, PTT, and D-dimer) remained within normal reference intervals, but platelet aggregation curves were blunted suggesting a decrease in platelet function. A platelet functional defect was suspected, but the mechanism of the defect could not be determined.

There are a number of ways that platelet function could be affected during leptospirosis. Spirochetes in the genus *Borrelia* have been shown to bind platelets directly,<sup>3-6</sup> so similar assays were done with *Leptospira interrogans* serovar Pomona. The third manuscript, "*Leptospira interrogans* serovar Pomona infection in guinea pigs and *in vitro* evidence of leptospire binding of platelets", demonstrates hemorrhage in a guinea pig model of serovar Pomona infection and provides *in vitro* evidence of platelet leptospire binding.

Hemorrhage was temporally correlated with a decrease in platelet count similar to the canine model. Microtiter assays show that leptospire bind to platelet monolayers, but do not bind to wells without platelets or wells containing platelet poor plasma or fibrinogen. When activated platelets and leptospire are incubated and fluorescent stained, large aggregates form. Incubation of leptospire with non-activated platelets does not result in the formation of aggregates. Binding was not inhibited with anti- integrin  $\alpha\text{IIb}\beta_3$  antibody as it is in *Borrelia*.<sup>4</sup>

The canine studies reported in this dissertation are important foundation work for further study of the pathogenesis of canine leptospirosis and the development of treatment and prevention strategies. “Clinical and pathologic comparison of acute canine leptospirosis caused by two strains of *Leptospira kirschneri* serovar Grippotyphosa” is the first published experimental study of disease caused by serovar Grippotyphosa after mucous membrane (conjunctival) exposure. Previous experimental models of canine leptospirosis have used subcutaneous, intraperitoneal, intramuscular, or intravenous inoculation techniques rather than a natural route of exposure. This model of mucous membrane inoculation more closely assimilates natural disease, so the incubation period, clinical signs, gross and histologic lesions, immune responses, and serum biochemical alterations produced through the use of this model should be similar to that in natural disease making it the model of choice for experimental studies and testing treatment regimens and disease prevention strategies such as vaccines.

A number of other studies could directly follow this work. An ultrastructural study comparing renal lesions caused by serovars Grippotyphosa and Pomona is indicated since lesions detected by light microscopy did not correlate well with parameters measuring organ

function. Renal inflammation is much more severe in serovar Pomona infected dogs than those infected with serovar Grippotyphosa, but biochemical abnormalities suggest renal failure in only the latter. In addition, this model of canine infection could be used in the future to test additional serovars emerging in the canine population or to test antibiotic protocols. Our research group has already used this model of canine leptospirosis using conjunctival inoculation to test the efficacy of whole-cell leptospiral vaccines. Dogs were vaccinated at 9 and 11 weeks with a 1 ml containing  $1 \times 10^9$  thimerosal killed leptospires. Three weeks after the second vaccination, dogs were challenged with serovar Grippotyphosa via the conjunctiva. Control (non-vaccinated) dogs had clinical signs, histologic lesions, and biochemical abnormalities to those described in “Clinical and pathologic comparison of acute canine leptospirosis caused by two strains of *Leptospira kirschneri* serovar Grippotyphosa”, but vaccinated dogs were protected from clinical disease.

There are several reasons to study leptospirosis in a guinea pig model. Guinea pigs are less expensive, more uniform in condition, and easier and less dangerous to restrain than dogs. As opposed to smaller laboratory animals, guinea pigs are large enough for small repeated blood samples or large single sampling for multiple tests at necropsy. Further studies should address the function of platelets in *Leptospira* infected guinea pigs, and the function of platelets after exposure to live or attenuated leptospires and extracted leptospiral lipoproteins or LPS. Specific mechanisms of leptospire binding of platelets need to be examined further through a more extensive panel of potential inhibitors. Integrin  $\alpha\text{IIb}\beta_3$  was a good candidate for initial studies because it is the most abundant receptor on the platelet surface, but blocking antibodies did not result in the inhibition of binding. Testing of

additional inhibitors was limited by the volume of platelets that can be obtained for study at one time and the availability of reagents with guinea pig specificity.

## REFERENCES

1. Nielsen JN, Cochran GK, Cassells JA, et al. *Leptospira interrogans* serovar Bratislava infection in two dogs. *J Am Vet Med Assoc* 1991; 199: 351-352.
2. Casella G, Scatena LF. Mild pancreatitis in leptospirosis infection. *Am J Gastroenterol* 2000; 95: 1843-1844.
3. Coburn J, Leong JM, Erban JK. Integrin  $\alpha\text{IIb}\beta_3$  mediates binding of the Lyme disease agent *Borrelia burgdorferi* to human platelets. *Proc Natl Acad Sci U S A* 1993; 90: 7059-7063.
4. Coburn J, Barthold SW, Leong JM. Diverse Lyme disease spirochetes bind integrin  $\alpha\text{IIb}\beta_3$  on human platelets. *Infect Immun* 1994; 62: 5559-5567.
5. Leong JM, Morrissey PE, Ortega-Barria E, et al. Hemagglutination and proteoglycan binding by the Lyme disease spirochete, *Borrelia burgdorferi*. *Infect Immun* 1995; 63: 874-883.
6. Alugupalli KR, Michelson AD, Barnard MR, et al. Platelet activation by a relapsing fever spirochaete results in enhanced bacterium-platelet interaction via integrin  $\alpha\text{IIb}\beta_3$  activation. *Mol Microbiol* 2001; 39: 330-340.

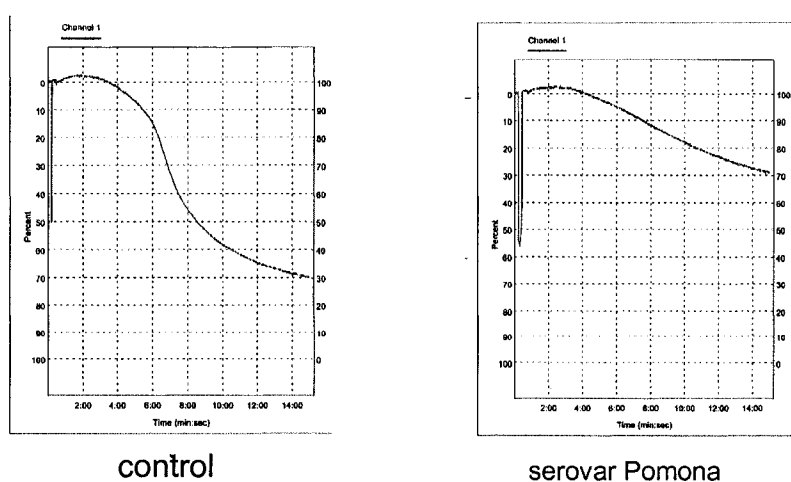
## **APPENDIX. PRELIMINARY PLATELET FUNCTION STUDIES IN SEROVAR POMONA INFECTED DOGS**

*Leptospira interrogans* serovar Pomona infected dogs hemorrhage into the lungs, kidneys, and gastrointestinal tract, but assays of clotting factors (PTT, PT) and fibrinolysis (D-dimer) fail to detect abnormalities in these dogs. Platelet numbers in affected dogs were decreased from baseline values at day 10 post inoculation (PI), but were considered adequate for hemostasis. Platelet dysfunction as a cause of hemorrhage in acute leptospirosis has not been previously studied, so platelet aggregation assays were done on a subset of infected animals to test the hypothesis that platelet function is altered in dogs infected with serovar Pomona.

A platelet aggregometer was used to assess the platelets' contribution to hemostasis *in vitro*. Control dog aggregation responses were compared to those of animals with clinical disease through the use of optical and impedance aggregometry methods. Optical platelet aggregometry measures changes in optical density of platelet rich plasma with a standardized platelet count whereas impedance aggregometry measures the change in resistance on an electrode caused by formation of a platelet plug in a sample of whole blood. Aggregation is measured after the addition of a strong agonist such as collagen or thrombin. The addition of a soluble agonist to a stirred platelet suspension induces activation of integrin  $\alpha_{IIb}\beta_3$ , converting it from a low to high-affinity receptor capable of binding soluble fibrinogen, an abundant plasma protein. Fibrinogen cross-links adjacent activated platelets leading to stable platelet aggregation, which is measured as a change in light transmittance or electrical impedance in optical or impedance aggregometry, respectively.

Blood was collected from a healthy control dog and two serovar Pomona inoculated dogs for platelet aggregometry. Using a 22 gauge needle, 9 volumes whole blood were drawn into tubes containing 1 volume 0.105 M sodium citrate. For impedance aggregometry, 1 ml of blood was diluted with 1ml of 0.9% NaCl before samples were run in duplicate on a platelet aggregometer (Chronolog 530-VS, Chronolog Corp., Havertown, PA). Additional steps were required to use the optical method. Blood with sodium citrate anticoagulant was transferred into polypropylene tubes, and centrifuged for at 1300 x g for three intervals of 90 seconds to obtain platelet rich plasma (PRP). PRP was gathered in a separate polypropylene tube after each interval of centrifugation. Platelet counts were done on PRP using a Petroff-Hausser counting chamber and 250  $\mu$ l samples of PRP with approximately  $2.5 \times 10^5$ / ml were used in the optical aggregometry studies. After PRP was obtained, the remaining constituents of the original sample were centrifuged at 1800 x g for 10 minutes to obtain platelet poor plasma (PPP) to use as an optical density standard representing 100% platelet

Figure 1. Platelet aggregation measured by impedance aggregometry was decreased in infected animals at 19 days post inoculation. The aggregation curve of an infected dog at 19 days post inoculation is blunted when compared to a control with a similar platelet count.



aggregation. Readings were obtained in duplicate for 7-14 minutes after the addition of 4  $\mu$ l of 1 mg/ml collagen as an agonist. Aggregation curves from infected dogs were compared to curves obtained from control dogs.

Preliminary results suggest that platelet function as measured by the platelet aggregation response is decreased in dogs infected with serovar Pomona. Altered platelet function in serovar Pomona infection would result in defective platelet plug formation and hemorrhage at the sites of endothelial damage. To better understand platelet function in leptospirosis additional platelet aggregometry studies should be done at 10 days post-inoculation using the canine model of serovar Pomona infection as that is when the most severe clinical hemorrhage occurs. Since platelet numbers are decreased in infected dogs during that time period, it will be necessary to perform optical aggregometry on samples of a standardized platelet count, so platelet aggregation can be compared between samples without interpretation being complicated by any difference in platelet numbers between animals. In addition, platelet aggregation should be assayed in samples obtained from control dogs and incubated with live leptospire or leptospiral extracts. A complete study comparing platelet aggregation of infected animals to platelets incubated *in vitro* with live leptospire will help determine whether altered platelet function is a direct effect of live leptospire, or occurs as a result of altered biochemical parameters in diseased animals.